

# The Impact of Uterine Artery Embolization Prior to Hysterectomy

Sumedha S Pathade<sup>1</sup>, Shruti A Panchbudhe<sup>2</sup>, Prasad Deshmukh<sup>3</sup>, Aditya Rajiv Nimbkar<sup>4</sup>

Received on: 05 April 2022; Accepted on: 31 August 2022; Published on: 31 January 2023

## ABSTRACT

**Aim:** Hysterectomy's role and efficacy for symptomatic uterine fibroids are well-established and undisputed. Before performing a hysterectomy in a large uterus, lowering uterine vascularity can aid in optimizing the surgery, reducing operating time, and, most importantly, minimizing the blood loss during the procedure.

**Background:** Uterine artery embolization (UAE) was introduced for the management of symptomatic uterine fibroids (leiomyomas) in 1995. Uterine artery embolization treatment of fibroids is performed worldwide.

**Case description:** A 40-year-old female with complaints of dysmenorrhea and heavy menstrual bleeding with a palpable 28-week mass arising from the pelvis with severe anemia was treated by performing preoperatively UAE followed by abdominal hysterectomy to minimize the blood loss.

**Conclusion:** This case report encourages offering UAE before abdominal hysterectomy to reduce intraoperative blood loss, thereby enhancing rapid postoperative recovery for large uteri.

**Clinical significance:** Performing UAE before hysterectomy reduces perfusion of myometrium as well as the fibroid, thereby minimizing the blood loss and need for blood transfusions, thus encouraging its use in the management of large fibroids.

**Keywords:** Hysterectomy, Leiomyoma, Magnetic resonance imaging, Uterine artery embolization.

*Journal of South Asian Federation of Obstetrics and Gynaecology* (2022); 10.5005/jp-journals-10006-2136

## INTRODUCTION

Uterine artery embolization was introduced for the treatment of symptomatic uterine fibroids (leiomyomas) in 1995.<sup>1</sup> Uterine artery embolization treatment of fibroids is performed worldwide. It uses a form of real-time X-ray called fluoroscopy to guide the delivery of embolic agents to the fibroids. These agents block the arteries to the fibroids and cause the fibroids to shrink in size. The main indication for the UAE is symptomatic fibroids (causing heavy menstrual bleeding, dysmenorrhea, pain, dyspareunia, or other pressure effects on the urinary or gastrointestinal tract) in women who desire treatment. The technique has been recommended by NICE for this indication. The combined technique is beneficial for women who are unwilling to receive a blood transfusion (such as Jehovah's witnesses).<sup>2</sup>

## CASE DESCRIPTION

A 40-year-old female, Para-2 Living 2 with previous 2 vaginal deliveries came to the outpatient department at our tertiary care hospital, with complaints of heavy menstrual bleeding and passage of clots from the last 6 cycles. She also had severe dysmenorrhea from the last 3 cycles. However, she had no bladder or bowel complaints. Her menstrual cycles were of 20–28 days in duration, regular, with soakage of 6–7 pads/day, and with the passage of clots. Past medical and surgical history was insignificant. The patient had severe pallor with a pulse of 90/min, and blood pressure was normal on general examination. On per-abdominal examination, a pelvic mass measuring 28 weeks was felt with side-to-side mobility, which was firm in consistency. On per-speculum examination, the cervix and vagina appeared healthy. However, the cervix appeared to be pulled up. On per-vaginal examination, the uterus was 28 weeks, firm in consistency, and anteverted with free fornices bilaterally.

<sup>1–4</sup>Department of Obstetrics and Gynaecology, Lokmanya Tilak Municipal General Hospital, Mumbai, Maharashtra, India

**Corresponding Author:** Sumedha S Pathade, Department of Obstetrics and Gynaecology, Lokmanya Tilak Municipal General Hospital, Mumbai, Maharashtra, India, Phone: +91 8097300196, e-mail: pathadesumedha@gmail.com

**How to cite this article:** Pathade SS, Panchbudhe SA, Deshmukh P, et al. The Impact of Uterine Artery Embolization Prior to Hysterectomy. *J South Asian Feder Obst Gynae* 2022;14(6):747–749.

**Source of support:** Nil

**Conflict of interest:** None

A complete hemogram on routine investigational workup showed hemoglobin of 4 gm%. Her abdominal and pelvic ultrasound revealed a well-defined solid cystic lesion, measuring approximately 17.2 × 16 × 13.2 cm, in the pelvis with the uterus not seen separately from the lesion with solid components showing mild internal vascularity with no evidence of calcification. In light of the ultrasound findings, magnetic resonance imaging (MRI) of the abdomen and pelvis showed a uterus measuring 21 × 17.7 × 12.7 cm with a well-defined lesion in the posterior wall of the uterus extending from the fundus to the lower uterine segment. It appeared isointense on T1, hypointense on T2 FLAIR, and no diffusion restriction on diffusion-weighted imaging, suggestive of posterior-wall uterine fibroid with cystic degeneration.

Preoperatively, the patient was transfused 4 units of packed red cells to achieve a hemoglobin level of 9 gm%. Following a discussion of treatment options with a multidisciplinary approach involving the intervention of radiologists and anesthesiologists for preoperative optimization, UAE followed by hysterectomy was

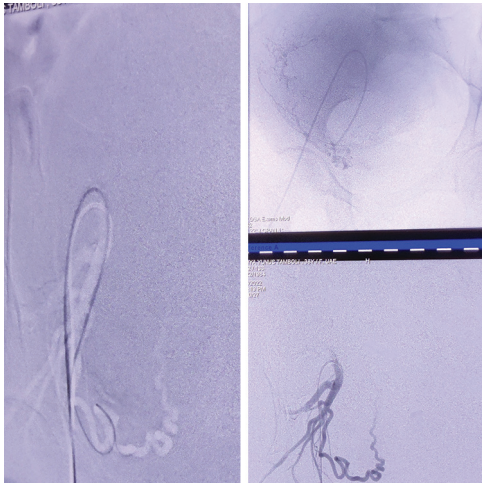


Fig. 1: Uterine artery embolization

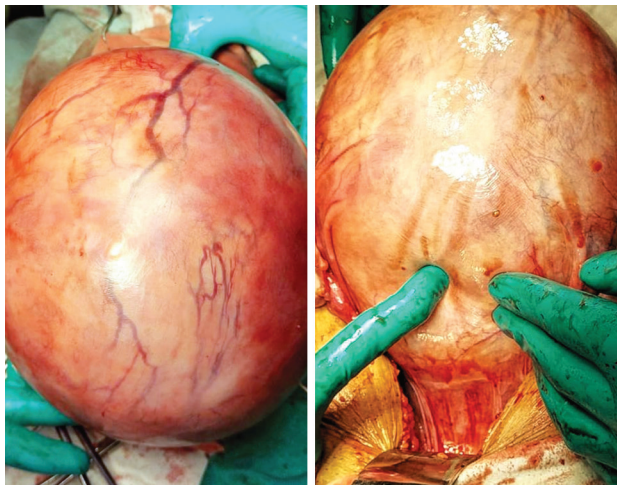


Fig. 2: Intraoperative findings of leiomyoma: thrombosed vessels seen

agreed upon. Using the Seldinger procedure, a 5-French preshaped catheter was surpassed into the uterine artery by insertion and navigation through the right femoral artery. Once an optimal location was visualized on angiography, particulate material in the form of polyvinyl alcohol (PVA) was injected to obliterate the vessels and their collaterals, until no reflux was visualized in the surrounding vessels (Fig. 1). The operative procedure was planned to be performed 24 hours after UAE. After taking an infra-umbilical vertical midline incision with paraumbilical extension, a 17 cm × 16 cm × 13 cm posterior-wall intramural fibroid, cystic and solid intermittent consistency, was seen intraoperatively, which was remarkably pale and avascular, along with a left-sided 6 cm × 6 cm simple cyst (Fig. 2). The decision to do an abdominal hysterectomy with left-sided salpingo-oophorectomy along with right-sided salpingectomy was undertaken. There was significantly reduced blood loss intraoperatively compared with similar cases in which UAE was not performed before hysterectomy. As a result of this, there was an insignificant drop in postoperative haemoglobin, which was 8.7 gm%. The patient had an uneventful recovery with usual postoperative care, and thromboprophylaxis with unfractionated

heparin was given for 10 days. She was given parenteral iron as per her hemoglobin deficit. Suture removal was done on day 14. Histopathology confirmed the diagnosis of leiomyoma and left-sided follicular cyst. The uterus weighed 3800 gm.

## DISCUSSION

Hysterectomy's role and efficacy for symptomatic uterine fibroids are well-established and undisputed. Hysterectomy is also linked to high patient satisfaction, with a significant majority of patients reporting enhanced quality of life following the procedure. Before a hysterectomy, lowering uterine vascularity can aid in optimizing the surgery, reducing operating time, and, most importantly, minimizing blood loss during the procedure.

Hillis et al.,<sup>3</sup> in their study comparing uterine size and risk of problems among women undergoing abdominal hysterectomy for leiomyomas, observed a substantial increase in complications when uterine weight surpassed 500 gm, which corresponded to a uterine size of around 14–18 weeks. They also discovered that women who had a uterus weight of more than 500 gm had a higher risk of intraoperative bleeding and postoperative complications such as cuff cellulitis, pyrexia, and pulmonary embolism. Other preoperative options for minimizing blood loss included using gonadotrophin-releasing analog agonists. However, it is not of much significance if the uterine size is more than 18 weeks. deSouza and Williams incorporated MRI for seeing perfusion in both the myometrium and the fibroid and observed that there was a drastic reduction in the immediate aftermath of embolization.<sup>4</sup> In a study conducted by Maria et al. between 2006 and 2014, when compared with controls, the estimated blood loss in the preoperative UAE group was considerably lower, and the control group had more complication rates than the UAE group (61.7% vs 21.7%).<sup>5</sup>

Uterine artery embolization was undertaken since there were no absolute contraindications to the procedure like active genital infection, doubtful diagnosis due to inaccurate clinical examination or imaging studies, and pregnancy. Also, the relative contraindications like narrow-stalked, pedunculated submucosal fibroids or large intracavity submucosal fibroids where there is a risk of significant fibroid sloughing into the endometrial cavity, leading to cervical obstruction and occasionally sepsis due to slough accumulation, were excluded.

Preprocedure care includes prophylactic antibiotics. Both the interventional radiologist and the gynecologist must fully evaluate a patient before recommending UAE before hysterectomy as a treatment for symptomatic fibroids. Although protocols necessitate performing preprocedural MRI, in our view, MRI also provides a clear diagnosis and identifies fibroid location according to the International Federation of Gynecology and Obstetrics classification system. It also aids to exclude occult malignancy, such as leiomyosarcoma. The materials used for the procedure include tris-acryl gelatin (TAG) spheres, non-spherical PVA and spherical PVA or the use of coils. In our study, we used PVA of size 300–500 microns for better embolization of vessels. Other larger sizes include 500–600 microns or 700–900 microns, which aid in embolizing the ovarian anastomoses, which in addition, also supply the uterine fibroid. Postprocedure complications include acute-phase complications such as pain, postembolisation syndrome, sepsis, bleeding, subacute and chronic-phase complications, transient or permanent amenorrhea, endometritis, urinary retention, and uterine necrosis.

## CONCLUSION

This case report encourages offering UAE before abdominal hysterectomy to reduce intraoperative blood loss and reduces operative time, thereby enhancing rapid postoperative recovery. The procedure is safe and effective in skilled hands. Performing MRI prior to UAE aids in differentiating leiomyoma from its malignant variant and knowing the extent of leiomyoma. This combined technique should be considered in selected patients where facilities for interventional radiologists are available. A multidisciplinary team approach is mandatory to execute this combined technique.

## REFERENCES

1. Ravina JH, Herbreteau D, Ciraru-Vigneron N, et al. Arterial embolisation to treat uterine myomata. *Lancet* 1995;346(8976): 671–672. DOI: 10.1016/s0140-6736(95)92282-2.
2. Royal College of Radiologists and Royal College of Obstetricians and Gynaecologists. Clinical recommendations on the use of uterine artery embolization in the management of fibroids. Report of a Joint Working Party. RCOG Press: London; 2001.
3. Hillis S, Marchbanks PA, Peterson HB. Uterine size and risk of complications among women undergoing abdominal hysterectomy for leiomyomas. *Obstet Gynecol* 1996;87(4):539–543. DOI: 10.1016/0029-7844(95)00478-5.
4. deSouza NM, Williams AD. Uterine arterial embolization for leiomyomas: perfusion and volume changes at MR imaging and relation to outcome. *Radiology* 2002;222(2):367–374. DOI: 10.1148/radiol.2222010584.
5. Maria FA, Raj S, Alexander B, et al. A retrospective study on preoperative uterine artery embolization before hysterectomy [25E]. *Obstet Gynecol* 2016;(127):49S. DOI: 10.1097/01.AOG.0000483850.79957.88.