

CASE REPORT

Large Ovarian Dermoid, a Cause for Fetal Growth Restriction and Oligohydramnios: Rare Instance in Literature

Sonal Agarwal¹, Anupma A², Avir Sarkar³, Jagdish C Sharma⁴

Received on: 23 July 2021; Accepted on: 26 August 2021; Published on: 31 January 2023

ABSTRACT

Ovarian dermoids mostly remain asymptomatic during pregnancy. Large dermoids may present with torsion, hemorrhage, or rupture. However, a dermoid cyst causing fetal growth restriction (FGR) and oligohydramnios is a very rare entity. The authors report a case of a large ovarian dermoid (15 × 12 cm) hampering intrauterine fetal growth. Due to the coronavirus disease-2019 (COVID-19) lockdown, the patient was unable to get ultrasound examinations in early gestation, and thereby, surgical intervention was not possible during the second trimester. As a result, this growing teratoma finally led to FGR by either exerting a pressure effect upon the uterus or by dwindling its blood supply.

Keywords: Dermoid cyst, Fetal growth restriction, Oligohydramnios, Teratoma.

Journal of South Asian Federation of Obstetrics and Gynaecology (2022); 10.5005/jp-journals-10006-2031

INTRODUCTION

Ovarian tumors are not common during pregnancy. They are present in 0.3% of pregnancies and are usually detected between 16 and 20 weeks of gestation. Dermoids, being the most common benign ovarian neoplasm in pregnancy, remain mostly asymptomatic.¹ Majority are incidentally diagnosed during antenatal ultrasounds. Some become symptomatic when they present with acute pain and tenderness owing to torsion, hemorrhage, or rupture. It is often advocated to remove adnexal masses more than 5 cm in diameter. The best time for surgical intervention is the second trimester. The authors hereby report a case of a huge ovarian dermoid cyst which resulted in fetal growth restriction (FGR) and oligohydramnios, the rarest of the complications to be ever noticed till date.

CASE DESCRIPTION

A 25-year-old second gravida with previous one Cesarean delivery 3 years back was referred to us at the 34-week period of gestation (POG) due to a large complex cyst in left ovary. The cyst was unilocular, measuring 12.5 × 13.7 cm, with mural components and multiple thin, echogenic bands with dot and dash patterns suggestive of a dermoid cyst. It was an asymptomatic cyst discovered incidentally during an ultrasound examination at the 32-week POG. Coming from a rural background, prolonged lockdown in the country due to the COVID-19 pandemic prevented her from getting easy access to medical facilities for ultrasounds during the early antenatal period. Thus, there were no dating and anomaly scans till now.

During her first visit to our antenatal clinic at the 34-week POG, her general condition was fair and vitals were stable. On per abdominal examination, fundal height was corresponding to the 36-week size gravid uterus with a symphysio-fundal height of 35.8 cm. However, a solid-cystic mass could be vaguely appreciated toward the left flank. Fetus was in longitudinal lie, with cephalic presentation, and fetal heart rate was around 140 beats per minute. An ultrasound conducted in our clinic the same day showed a single live intrauterine fetus corresponding to 30 weeks of gestation! It was in cephalic presentation. There were no gross structural abnormalities. Placenta was located in fundo-anterior segment of the uterus with grade II maturity. Liquor was on the lower side with

¹⁻⁴Department of Obstetrics and Gynaecology, ESIC Medical College and Hospital, Faridabad, Haryana, India

Corresponding Author: Sonal Agarwal, Department of Obstetrics and Gynaecology, ESIC Medical College and Hospital, Faridabad, Haryana, India, e-mail: dr.sonalagarwal12@gmail.com

How to cite this article: Agarwal S, Anupma A, Sarkar A, *et al.* Large Ovarian Dermoid, a Cause for Fetal Growth Restriction and Oligohydramnios: Rare Instance in Literature. *J South Asian Feder Obst Gynae* 2022;14(6):744–746.

Source of support: Nil

Conflict of interest: None

an amniotic fluid index (AFI) of 6.0 cm. The estimated fetal weight was around 1.4 kg. Umbilical artery Doppler studies were, however, normal with good diastolic flow. Fetal non-stress tests (NSTs) were suggestive of a reassuring fetal status. There was no history of increased blood pressure records and no history suggestive of leaking per vaginum or recent fever, diarrhea, and dehydration. Coming from a lower-middle socioeconomic class, her nutrition status was fairly good. She was not addicted to intake of alcohol, caffeine, or smoking. On detailed history taking, records of first pregnancy showed that the previous baby had a birth weight of 3.0 kg.

There was no other cause to which FGR and oligohydramnios could be attributed rather than the pressure effect of the huge size teratoma located in the left adnexa. Considering normal Doppler tracings, a conservative approach was done to continue pregnancy up to 37 weeks with biweekly NST and biophysical profile in antenatal clinic. Umbilical artery Doppler showed good diastolic flow till the term. At the 37-week gestation, fetal parameters were corresponding to 32 weeks with an estimated fetal weight of 1.7 kg. AFI gradually reduced to 4.5 cm, although gross fetal movements and breathing movements were noted. She underwent an elective Cesarean section as she was not willing for a trial of labor after a Cesarean.

Preoperative hematological investigations were within normal limits. Under spinal anesthesia, abdomen was opened by a lower

transverse incision. The previous scar was intact. Very minimal clear liquor was drained and a live born baby girl of 1.8 kg was delivered as cephalic with good APGAR scores of 9 and 10 at 1 and 5 minutes after birth, respectively. Placenta and membranes were delivered in toto. Uterus was normal in morphology and was stitched in two layers. Right fallopian tube and ovary were normal. Toward the left iliac and lumbar region, a large ovarian cyst with a smooth surface was noticed. It grossly measured around 15 × 12 cm and was ovoid in shape with three turns of torsion present in the tubo-ovarian segment (Fig. 1). A gentle detorsion followed by enucleation and cystectomy was done after careful preservation of the fimbrial end of the left fallopian tube. There was no intraperitoneal spillage of contents from the cyst prior to removal from the abdomen. On cut section, there was a presence of straw color fluid, pultaceous material, and hair, thereby assuring the diagnosis of a dermoid cyst (Fig. 2).

The baby was kept in neonatal intensive care unit (NICU) for 72 hours. Although initial feeds were started with expressed breast milk via spoon-feed, baby was soon shifted to the mother's side after 72 hours of observation. Exclusive breastfeeding was thereby initiated and both mother and baby were discharged under stable

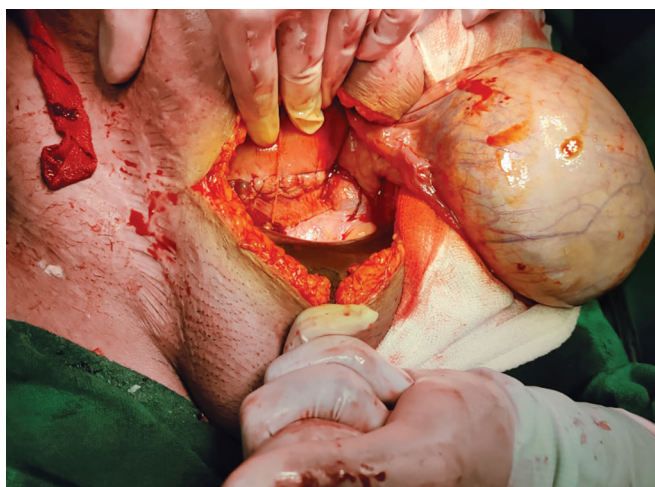


Fig. 1: Intraoperative picture of left adnexal cyst with smooth intact surface

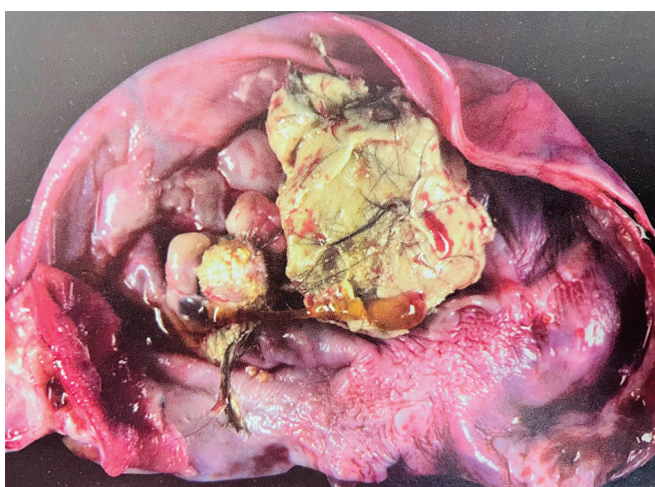

Fig. 2: Cut section of dermoid cyst showing hair and pultaceous material

condition after 5 days of hospital stay. Microphotographic study showed that the cyst was lined by flattened squamous epithelium along with hair follicles and skin appendages. There were focal areas of cartilage and sebaceous glands. There was no immature component or features of atypia, thus confirming the diagnosis of a mature cystic teratoma.

Both mother and baby are doing fine at 4 weeks postdelivery and will follow up in postpartum clinic at six weeks for examination and contraceptive counseling.

DISCUSSION

Dermoids constitute 20–40% of ovarian neoplasms in pregnancy.¹ Being the most common tumor, they generally remain asymptomatic throughout pregnancy. They are mostly diagnosed during routine antenatal ultrasounds and appear as unilocular or multilocular cystic adnexal masses with mural nodules and echogenic masses with posterior sound attenuation.² Complications in the form of torsion, infection, hemorrhage, rupture, and malignant transformations are mostly seen in the second trimester of pregnancy. However, dermoids causing intrauterine pressure effects leading to FGR is an extremely rare phenomenon to be observed.³ Index patient presented with intrauterine growth restriction that could not be attributed to any obstetric or medical cause other than the pressure effect of the huge left ovarian dermoid cyst of 15 × 12 cm.

Adnexal masses measuring less than 5 cm rarely cause symptoms. Ovarian masses measuring more than 5 cm should be followed up with serial ultrasounds. Ideal timing to go for surgical removal of large adnexal masses is the second trimester.⁴ Although risk of miscarriage following surgical resection of ovarian tumor during pregnancy is roughly around 2.8%, yet risk associated with torsion, hemorrhage, and preterm labor can be eventually averted through timely surgical interventions in the early second trimester.⁴ Unilateral simple ovarian cysts, 5–8 cm in size, should be evaluated sonologically up to 16–18 weeks and if they fail to regress or increase in size, surgical intervention should be undertaken by 18 weeks. During pregnancy, tumor markers are not reliable to assess the risk of malignancy of ovarian masses.¹ Had it not been the difficult coronavirus pandemic, diagnosis of this large-size dermoid cyst would have been possible in the early gestation. Timely surgical intervention would have prevented late complications like severe FGR and oligohydramnios in this pregnancy. Such large teratomas causing FGR can be explained by extrauterine pressure effects or due to tumor deriving its blood supply from the ovarian and uterine arteries predominantly.³

CONCLUSION

Surgical intervention of large adnexal masses during the second trimester of pregnancy can avert adverse outcomes like obstructed labor, dystocia, torsion, hemorrhage, and rupture of cysts. In index case, dermoid has caused FGR and oligohydramnios. Although very rare, yet such complications do occur at times. It is time for obstetricians to serially monitor all adnexal masses in pregnancy and timely intervene so that late complications can be avoided.

REFERENCES

1. Tariel O, Huissoud C, Rudigoz RC, et al. Presumed benign ovarian tumors during pregnancy. *J Gynecol Obstet Biol Reprod* 2013;42(8):842–855. DOI: 10.1016/j.jgyn.2013.09.038.

2. Sahin H, Abdullazade S, Sanci M. Mature cystic teratoma of the ovary: a cutting edge overview on imaging features. *Insights Imaging* 2017;8(2):227–241. DOI: 10.1007/s13244-016-0539-9.
3. Das R, Rajbhandari S. An ovarian dermoid cyst in pregnancy: a rare cause of intrauterine growth restriction. *Medphoenix* 2020;5(1):75–78. DOI: 10.3126/medphoenix.v5i1.31422.
4. Testa AC, Mascilini F, Quagliozi L, et al. Management of ovarian masses in pregnancy: patient selection for interventional treatment. *Int J Gynecol Cancer* 2021;31(6):899–906. DOI: 10.1136/ijgc-2020-001996.