

En Bloc Peritonectomy Specimen in a Case of Ovarian Cancer

Richi Khandelwal¹, Manoranjan Mahapatra², Jita Parija³, Agniv Sarkar⁴, Smruti S Pattnaik⁵

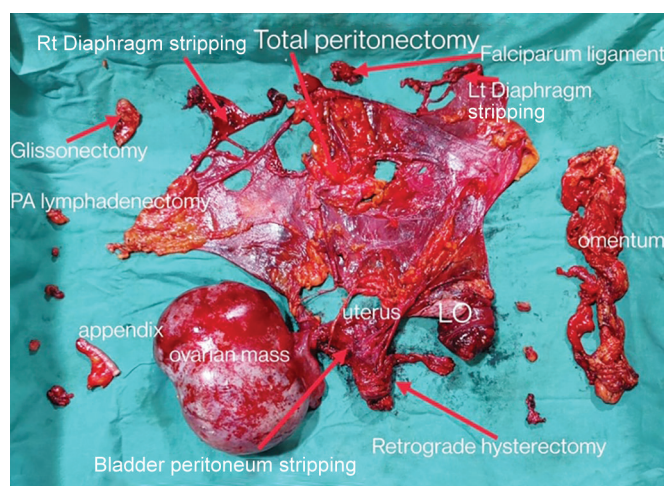
ABSTRACT

This is a picture showing en bloc peritonectomy specimen during primary cytoreduction on a case of ovarian cancer.

Keywords: Adjuvant chemotherapy, Epithelial ovarian cancer, Peritonectomy.

Journal of South Asian Federation of Obstetrics and Gynaecology (2021): 10.5005/jp-journals-10006-1924

The picture shows peritonectomy (pelvic, abdominal, and diaphragmatic stripping) along with the ovarian mass, uterus, and contralateral adnexa removed en bloc with appendix, omentum, para-aortic lymph node, and part of Glisson's capsule.



¹⁻⁵Department of Gynecological Oncology, Acharya Harihar Post Graduate Institute of Cancer, Cuttack, Odisha, India

Corresponding Author: Richi Khandelwal, Department of Gynecological Oncology, Acharya Harihar Post Graduate Institute of Cancer, Cuttack, Odisha, India, Phone: +91 9785077004, e-mail: richi_kh@yahoo.com

How to cite this article: Khandelwal R, Mahapatra M, Parija J, *et al.* En Bloc Peritonectomy Specimen in a Case of Ovarian Cancer. *J South Asian Feder Obst Gynae* 2021;13(4):277.

Source of support: Nil

Conflict of interest: None