

Efficacy of Chromohysteroscopy for Evaluation of Endometrial Pathologies in Abnormal Uterine Bleeding

Anitha Vijay¹, Vijaya Koothan², Madhangi V Baskaran³

ABSTRACT

Aim: To investigate the efficacy of chromohysteroscopy in evaluation of endometrial pathologies in patients with abnormal uterine bleeding (AUB).

Materials and methods: Fifty patients with AUB without any macroscopic abnormalities of endometrium on hysteroscopy were included in the study. After instillation of methylene blue dye, chromohysteroscopy was performed. The pattern of endometrial staining was noted. Biopsies were taken from stained and unstained areas and sent for histopathological examination.

Results: Of the 50 patients included in the study, 36 had diffuse staining and 14 had focal staining pattern of endometrium. Of the 13 cases with endometrial pathologies on histopathology, 10 had focal staining pattern. The diagnostic accuracy of the stained endometrium in cases with focal staining, for detection of endometrial pathologies was statistically significant when compared to the unstained areas with a sensitivity of 76%, specificity 89%, positive predictive value 71% and negative predictive value of 92%.

Conclusion: Chromohysteroscopy helps improve the diagnostic accuracy of conventional hysteroscopy.

Clinical significance: Chromohysteroscopy can be used as an adjunct to identify the target areas to be biopsied in cases with macroscopically normal appearing endometrium on hysteroscopy.

Keywords: Abnormal uterine bleeding, Chromohysteroscopy, Endometrial pathologies.

Journal of South Asian Federation of Obstetrics and Gynaecology (2019): 10.5005/jp-journals-10006-1719

INTRODUCTION

Abnormal uterine bleeding (AUB) is defined as bleeding from the uterus that differs in frequency, regularity, duration or amount, from normal bleeding in the absence of pregnancy.¹ The prevalence of AUB in the reproductive years is high and it is estimated that it affects 30% of all women at some time in their lives. Approximately 5% seek care each year and up to 30% of all visits to gynecologists are for an AUB symptom.² The reported prevalence of AUB in India is around 17.9%.³

To standardize the nomenclature of AUB, a new etiopathogenesis based system known by the acronym PALM-COEIN was introduced by FIGO⁴ where PALM denotes structural causes and COEIN denoting nonstructural causes.

Among the various diagnostic modalities available for structural causes of AUB, hysteroscopy is both accurate and feasible in the finding of intrauterine abnormalities⁵ and is generally considered as the "gold standard". Yet, it is difficult to identify problematic areas during hysteroscopy in macroscopically normally appearing endometrium.

Chromoendoscopy or chromoscopy is a technique involving topical application of stains or dyes to tissues during endoscopic examination to enhance and facilitate detection and identification of abnormal cellular growth. Methylene blue in particular, stains absorptive and structurally damaged epithelium is extensively used for identifying abnormalities in gastrointestinal tract.⁶ Similarly, chromohysteroscopy is a method which has been studied earlier in subfertile women with implantation failure.⁷

This study aims at investigating the efficacy of this new method along with conventional hysteroscopy in evaluation of endometrial pathologies of patients with AUB.

MATERIALS AND METHODS

This interventional cross-sectional study was carried out in the department of Obstetrics and Gynecology, Aarupadai Veedu

¹⁻³Department of Obstetrics and Gynecology, Aarupadai Veedu Medical College, Puducherry, India

Corresponding Author: Anitha Vijay, Department of Obstetrics and Gynecology, Aarupadai Veedu Medical College, Puducherry, India, e-mail: dranithav_83@yahoo.co.in

How to cite this article: Vijay A, Koothan V, Baskaran MV. Efficacy of Chromohysteroscopy for Evaluation of Endometrial Pathologies in Abnormal Uterine Bleeding. *J South Asian Feder Obst Gynae* 2019; 11(5):301–304.

Source of support: Nil

Conflict of interest: None

Medical College and Hospital, over a period of 1 year from August 2015 to July 2016. A total of 50 consecutive women attending the gynecological OPD with complaints of AUB were included in the study and informed written consent was taken from all the participants. Institutional research and ethical committee clearance were obtained.

Detailed history taking and clinical examination was done and the women were subjected to relevant investigations according to the department protocol. Women with suspected pregnancy, bleeding disorders, endocrinological abnormalities and uterine cavity abnormalities like fibroid were excluded from the study.

After explaining the procedure, all patients were subjected to chromohysteroscopy guided biopsy under IV sedation, between 20th and 25th day of menstrual cycle. In post-menopausal bleeding, cases were taken up in the first visit. Initially a diagnostic hysteroscopy was performed with a 30° rigid telescope with 2.9 mm diameter and abnormal areas if any were noted.

Then, hysteroscope was withdrawn and 5–10 mL of diluted 1% methylene blue was instilled through Karman's Cannula.

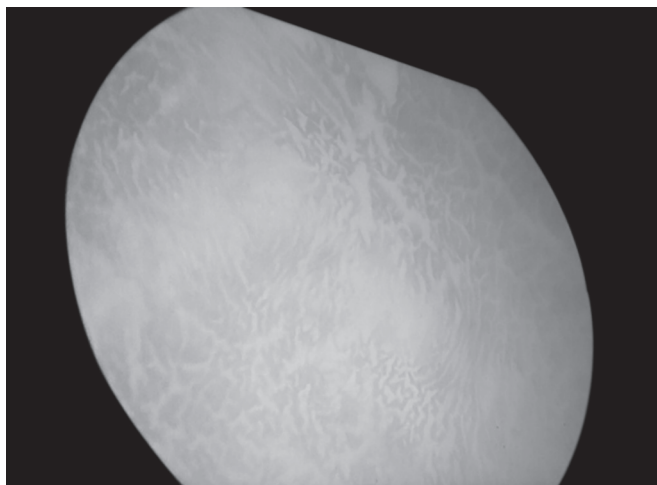


Fig. 1: Chromohysteroscopic view of diffusely stained endometrium

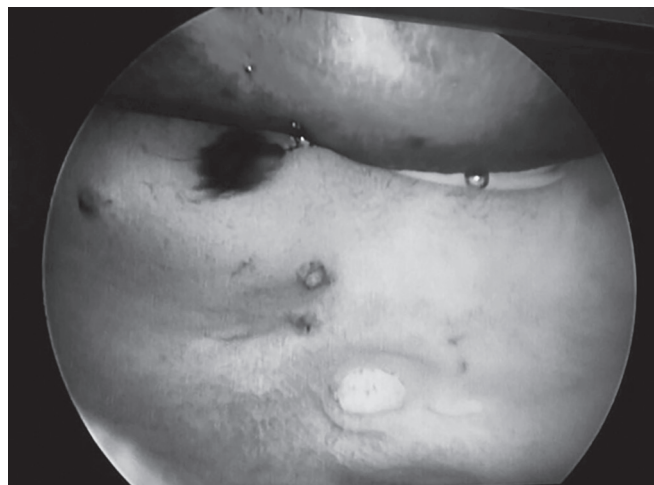


Fig. 2: Chromohysteroscopic view showing focal dark staining in the anterior wall of uterus

Table 1: Frequency distribution of staining pattern with methylene blue in hysteroscopy

Staining pattern	n = 50	Percentage
Diffuse	36	72
Focal	14	28

Hysteroscope was reintroduced after 5 minutes and the staining pattern of endometrium was recorded. Those with uniform light staining with methylene blue dye were classified as diffuse staining pattern (Fig. 1) and those with dark staining in certain areas and light staining in remaining areas were classified under focal staining pattern (Fig. 2) for statistical convenience. In cases with focal staining pattern, hysteroscopy guided endometrial biopsy was taken separately from dark stained and light stained areas and were labelled separately. In cases with diffuse staining of endometrium, random endometrial biopsies were taken.

The tissues were sent for histopathological examination and the results were obtained. The patients were discharged 6 hours after the procedure. The collected data were tabulated and statistical analysis was done.

According to the findings, the patients were properly managed according to the department protocol.

RESULTS

Chromohysteroscopy was performed in 50 patients with no apparent macroscopic abnormality on conventional hysteroscopy. Data were analyzed using the SPSS statistical package version 16 (IBM, Armonk, NY, USA). Qualitative variables were expressed in terms of frequency and percentage. Chi-square test was used to find the association of endometrial pathologies with other qualitative variables. Sensitivity, specificity, positive and negative predictive values were also calculated to assess the diagnostic accuracy of chronic endometrial pathologies using histopathology as the gold standard. The *p* values less than 0.05 were considered to be statistically significant.

Out of 50 women in whom the procedure was performed, 36 (72%) had diffuse staining of endometrium whereas 14 (28%) had focal staining as shown in Table 1.

Table 2: Frequency distribution of histopathology report

Histopathology report	n = 50	Percentage
Normal	20	40
Hormonal imbalance	17	34
Endometrial pathologies	13	26
Nonspecific chronic endometritis	8	62
Simple endometrial hyperplasia	2	15
Complex endometrial hyperplasia with atypia	2	15
Endometrial carcinoma	1	8

Histopathological examination results of all the 50 patients are shown in Table 2. Those cases showing physiological changes were classified under normal and those cases with findings like disorderly endometrium, out of phase endometrium and those suggestive of luteal phase defects were grouped under hormonal imbalance. Out of the 13 cases where biopsy revealed endometrial pathologies, 8 (62%) cases were nonspecific chronic endometritis, 2 (15%) cases were simple endometrial hyperplasia, 2 (15%) were complex endometrial hyperplasia with atypia and there was 1 (8%) case of endometrial adenocarcinoma.

Of the 13 endometrial pathologies diagnosed on biopsy, chromohysteroscopy showed focal staining pattern in 10 (76.9%) cases and diffuse staining in 3 (23.1%). There were two cases of complex endometrial hyperplasia with atypia and one case of endometrial adenocarcinoma detected by methylene blue staining along with six cases of chronic endometritis and one case of simple endometrial hyperplasia.

Table 3 showed that the diagnostic accuracy of focal staining pattern in detection of endometrial pathologies is significantly higher than diffuse staining pattern with sensitivity (76%), specificity (89%), positive predictive value (71%) and negative predictive value (92%). Table 3 also shows that the finding of focal staining pattern correlates well with the result of histopathology.

The diagnostic accuracy of dark stained and light stained areas in focal staining pattern in detection of endometrial pathologies is shown in Table 4. In diffuse staining pattern, there was no such differentiation. It was observed that histopathological examination

Table 3: Diagnostic accuracy of focal staining in detection of endometrial pathologies

Staining pattern	n = 50 (%)	Endometrial pathologies (%)	Sensitivity	Specificity	PPV	NPV
Diffuse	36 (72)	3 (8)	23	10	8.3	28
Focal	14 (28)	10 (71)	76	89	71	92

Table 4: Diagnostic accuracy of dark and light stained areas in detection of endometrial pathologies on chromohysteroscopy

Variable	Staining pattern	n = 50	Endometrial pathologies	Sensitivity	Specificity	PPV	NPV	Significance value
Dark	Diffuse	36	3	23	10	8.3	28	$p < 0.001$
Stained	Focal	14	10	76	89	71	92	
Light	Diffuse	36	3	75	28	8.3	93	0.89
Stained	Focal	14	1	25	72	7.2	92	

Table 5: Frequency distribution of endometrial pathologies and their staining pattern

Method of diagnosis	n = 13	Percentage
Focal staining	10	76.9
Chronic endometritis	6	60
Simple endometrial hyperplasia	1	10
Complex endometrial hyperplasia with atypia	2	20
Endometrial carcinoma	1	10
Diffuse staining	3	23.1
Chronic endometritis	2	66
Simple endometrial hyperplasia	1	34

of dark stained areas was able to identify endometrial pathologies better than those with light staining and the difference was found to be statistically significant with a p value < 0.001 .

DISCUSSION

Diagnostic hysteroscopy is considered as a simple, safe, low-risk technique in evaluation of AUB and is gradually replacing the conventional procedure of dilatation and curettage. But several studies have shown that, while hysteroscopy was more sensitive than curettage in detecting endometrial polyps and submucous fibroids, it was less sensitive than curettage in detecting endometrial hyperplasia and endometrial carcinoma.⁸

Hence to improve diagnostic accuracy in cases where there is no gross abnormality of endometrium, chromohysteroscopy has been advocated. Chromoendoscopy has been widely used in gastrointestinal imaging.⁶ Marconi et al.^{9,10} and Kucuk and Safali¹¹ reported that the structural damage of endometrial cells allows passage of methylene blue dye into the cells resulting in dark blue staining.

In the present study, methylene blue dye was instilled after performing an initial diagnostic hysteroscopy and staining pattern was noted. Control group was not included to avoid unindicated hysteroscopies. Diffuse staining was seen in 72% of cases and focal staining was noted in 28% (Table 1).

The histopathological examination showed normal finding in 40% and hormonal imbalance in 34% of cases (Table 2). Of the eight cases of chronic endometritis, focal staining was noted in six cases and diffuse staining in two cases. One case of simple endometrial hyperplasia showed focal staining and one showed

diffuse staining. It is important to note that, all cases of complex endometrial hyperplasia with atypia and endometrial carcinoma showed focal staining (Table 5). It is similar to the study by Kucuk and Deveci which showed that chromohysteroscopy had greater accuracy in detecting pathologies in the endometrium.⁷

In our study, of the 13 cases (26%) with endometrial pathologies on histopathology report, 10 cases showed focal staining pattern as shown in Table 5, indicating that the pattern of focal staining correlates well with histopathology report.

In the present study, dark stained tissue biopsy in cases with focal staining, showed sensitivity of 76%, specificity 89%, positive predictive value of 71% and negative predictive value of 92% in detection of endometrial pathologies (Tables 3 and 4), with a statistically significant difference ($p < 0.001$) when compared to the light stained areas and also with the random biopsies of endometrial tissue in cases with diffuse staining. Singh et al.¹² in their study also suggested that diagnostic accuracy of stained tissue biopsy was higher.

CONCLUSION

Chromohysteroscopy is a simple, safe procedure which can help to improve the diagnostic accuracy of conventional hysteroscopy and can be done at no extra cost.

CLINICAL SIGNIFICANCE

Chromohysteroscopy can be used as an adjunct to identify the target areas to be biopsied in cases with macroscopically normal appearing endometrium on hysteroscopy.

REFERENCES

- American College of Obstetricians and Gynecologists. Management of acute abnormal uterine bleeding in nonpregnant reproductive-aged women. Committee Opinion No. 557. *Obstet Gynecol* 2013;121(4):891–896. DOI: 10.1097/01.AOG.0000428646.67925.9a.
- Liu Z, Doan QV, Blumenthal P. A systematic review evaluating health-related quality of life, work impairment, and health-care costs and utilization in abnormal uterine bleeding. *Value Health* 2007;10(3):183–194. DOI: 10.1111/j.1524-4733.2007.00168.x.
- Sharma A, Dogra Y. Trends of AUB in tertiary centre of Shimla hills. *J Midlife Health* 2013;4(1):67–68. DOI: 10.4103/0976-7800.109648.
- Munro MG, Critchley HO, Broder MS, et al. FIGO classification system (PALM-COIN) for causes of abnormal uterine bleeding in nonpregnant

- women of reproductive age. *Int J Gynaecol Obstet* 2011;113(1):3–13. DOI: 10.1016/j.ijgo.2010.11.011.
5. Van Dongen H, De Kroon CD, Jacobi CE, et al. Diagnostic hysteroscopy in abnormal uterine bleeding: a systematic review and meta-analysis. *BJOG* 2007;114(6):664–675. DOI: 10.1111/j.1471-0528.2007.01326.x.
 6. Wang KK, Okoro N, Prasad G. Endoscopic evaluation and advanced imaging of Barrett's esophagus. *Gastrointest Endosc Clin N Am* 2011;21(1):39–51. DOI: 10.1016/j.giec.2010.09.013.
 7. Kucuk T, Deveci S. Chromohysteroscopy for evaluation of endometrium in recurrent miscarriage. *Clin Exp Obstet Gynecol* 2008;35(2):133–136.
 8. Madan SM, Al-Jufairi ZA. Abnormal uterine bleeding. Diagnostic value of hysteroscopy. *Saudi Med J* 2001;22(2):153–156.
 9. Marconi G, Vilela M, Quintana R, et al. New observations on endometrial physiology after transcervical injection of methylene blue dye. *Fertil Steril* 2004;82(6):1700–1704. DOI: 10.1016/j.fertnstert.2004.07.947.
 10. Marconi G, Vilela M, Quintana R, et al. Endometrial lesions caused by catheter used for embryo transfers: a preliminary report. *Fertil Steril* 2003;80(2):363–367. DOI: 10.1016/S0015-0282(03)00607-1.
 11. Kucuk T, Safali M. "Chromo hysteroscopy" for evaluation of endometrium in recurrent in vitro fertilization failure. *J Assist Reprod Genet* 2008;25(2–3):79–82. DOI: 10.1007/s10815-007-9196-8.
 12. Singh N, Singh B. Chromohysteroscopy-a new technique for endometrial biopsy in Abnormal Uterine Bleeding (AUB). *Open J Obstet Gynecol* 2013;3(5):11–14. DOI: 10.4236/ojog.2013.35A1003.