

Fundal Rupture with Breech Expulsion through it in Primigravida: Role of Destructive Procedure (Decapitation) in Modern Obstetrics

Shalini Singh¹, Vimla Charan², Sudha Gandhi³

ABSTRACT

Aim: The aim of the study was to point out the problems faced at peripheral hospitals such as difficulties in assessment and management, and ultimately late referral in inevitable stage, hence increasing risk of maternal mortality and morbidity. The study also discusses the measures to be taken for the betterment, especially in developing countries.

Background: Uterus rupture secondary to obstructed labor especially in an unscarred uterus and primigravida is a rare and a life-threatening condition. It needs early detection and prompt management to avoid maternal morbidity, mortality, and stillbirths.

Case description: This is a case about 21-year primigravida at term gestation referred to our tertiary hospital from a peripheral hospital in view of an undelivered IUFD baby obstructed at the level of scapula with the head, both arms, and placenta already expelled out and further could not be delivered despite their efforts; peroperatively, it was a fundal rupture through which breech had expelled into abdomen and obstructed. Thus, only destructive procedure of decapitation was the method of choice to deliver the trunk through a ruptured fundus.

Conclusion: The patient remained stable throughout the surgery and in the postoperative period, and was discharged on the ninth day in a healthy condition.

Clinical significance: The case hold significance because of various challenges faced by us in management and problems at peripheral centers to be handled, better assessment, early referral in order to reduce maternal mortality, and stillbirth in a developing country such as India. We also discuss the significance of destructive procedures in modern obstetrics for developing countries.

Keywords: Decapitation, Destructive surgery, Fundal rupture, Obstructed labor, Ruptured uterus, Undelivered fetus.

Journal of South Asian Federation of Obstetrics and Gynaecology (2019): 10.5005/jp-journals-10006-1686

BACKGROUND

Obstructed labor is one of the common causes of maternal mortality and one of the leading causes of perinatal mortality.¹ It holds the case fatality rate of 87–100%.² The cases with an unduly prolonged and obstructed labor with a jammed fetal head are rarely seen in developed countries today but are still prevalent in the developing countries. It accounts for 8% of maternal deaths in developing countries annually.³ It is also one of the common causes of uterine rupture, hence increasing maternal mortality and morbidity. As per WHO, the prevalence of uterine rupture in developed countries is 0.006% but varies from 1 in 2,000 to 1 in 200 deliveries in developing countries.⁴ Rupture of the uterus during labor is a real catastrophic emergency. However, rupture is uncommon in an unscarred uterus.⁵ Primigravidas were thought to be immune against rupture but was proved incorrect.⁶ It is noticed that the incidence of rupture uterus (whether scarred or unscarred) has increased in the last decade.⁷ Hereby, we present a case of primigravida referred to us with a prolonged labor and a partially delivered baby with the head and upper limbs expelled and obstructed at the level of scapula. The decision for laparotomy was taken on complete clinical assessment and it was found that there was a fundal rupture through which lower limbs and breech had expelled and obstructed at the level of abdomen. The case holds significance because of various challenges faced by us in management. It was a dilemma and final decision was an aggressive procedure of decapitation to deliver the baby. With this case, we discuss the problems at peripheral centers to be dealt with, for better assessment, early referral in order to reduce maternal mortality, and stillbirth in developing countries. Also,

^{1–3}Department of Obstetrics and Gynecology, Panna Dhai Mahila Chikitsalaya, Rabindranath Tagore Medical College, Udaipur, Rajasthan, India

Corresponding Author: Shalini Singh, Department of Obstetrics and Gynecology, Panna Dhai Mahila Chikitsalaya, Rabindranath Tagore Medical College, Udaipur, Rajasthan, India, Phone: +91 9453042278, e-mail: shalini7679@gmail.com

How to cite this article: Singh S, Charan V, Gandhi S. Fundal Rupture with Breech Expulsion through it in Primigravida: Role of Destructive Procedure (Decapitation) in Modern Obstetrics. *J South Asian Feder Obst Gynae* 2019;11(3):220–223.

Source of support: Nil

Conflict of interest: None

we emphasize on the significance of destructive procedures that cannot be obsolete in developing countries.

CASE DESCRIPTION

A 21-year primigravida at a term gestation was referred to our tertiary hospital from a peripheral hospital (160 km away) in view of undelivered IUFD baby obstructed at the level of scapula with the head, both upper limbs, and placenta already expelled out. Baby could not be further delivered despite their efforts (Fig. 1). The patient had total two antenatal visits at nearby PHC. She had received 2 tetanus toxoids and erratic intake of iron and folic acid tablets. The patient reported at term to a nearby PHC in labor with

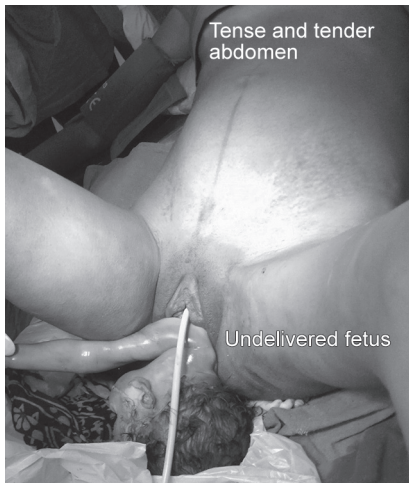


Fig. 1: Patient reported with partially delivered fetus obstructed at level of shoulders with both arms expelled out

a complaint of fever and decreased fetal movement for past three days. As per referral note, her ultrasonography done on day of admission confirmed IUFD. Though the duration of labor, any use of uterotonics, induction, augmentation, or instrumentation was not mentioned. The patient was referred to our center as the baby could not be delivered from the level of scapula. At the PHCs, they tried to complete the delivery (by fundal pressure and traction as per history elicited from attendants and patient herself), but failed and subsequently referred the woman to a tertiary care hospital with hemoglobin as 7.7 and B negative blood group. They had transfused one unit packed RBCs.

On admission at our center, the patient was stable hemodynamically. Though her pulse was 110/minutes and blood pressure 110/70, clinically pallor was present. Urgent emergency investigations were sent, primary measures were taken to maintain her vitals, and adequate blood and blood products were arranged. On clinical examination, per abdominally, it gave a picture of Bandl's ring with upper abdomen retracted and lower abdomen distended. On local examination, head and upper limbs had expelled but firmly obstructed at the level of scapula (Fig. 1), with skin peeling noticed, suggesting old IUFD. On per vaginal examination, the cervix seem soft and fingers could be easily swept throughout the rim but cannot be further inserted through the back of baby for evaluation of any undiagnosed obstructing mass. Baby did not appear to get delivered vaginally. The diagnosis and management was a dilemma, whether it was a Bandl's ring due to obstructed labor or undiagnosed mass like neural tube defects or sacrococcygeal teratoma was obstructing the delivery. Hence, the decision for laparotomy was taken with all consent in overall benefit of patient.

Investigations

Her urgent hemoglobin was 7.1 g%.

Surgery

On opening the abdomen by a modified phannenstiell incision, the condition was beyond our expectation. The breech and lower limbs were found lying in abdomen expelled out through a fundal rupture, which was resting upon around a 24-week-size uterus. There was around 200 cc of hemoperitonium, which was lesser than expected possibly because of impacted fetal part at the ruptured site (Fig. 2). Finally, the per operative diagnosis was fundal rupture

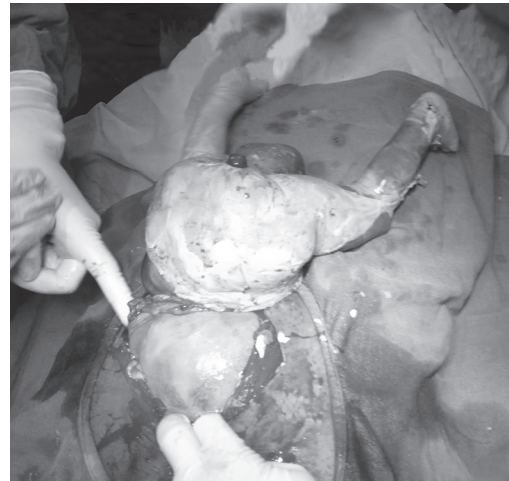


Fig. 2: On laparotomy, breech expelled through the ruptured fundus secondary to fundal pressure

with breech expulsion possibly due to injudicious use of oxytocin and fundal pressure at periphery hospital to facilitate delivery in obstructed situation. It portrayed the poor assessment of labor and fundal pressure. Though patient remained stable hemodynamically throughout our surgery, but the delivery of the baby was still a dilemma; hence, a decision for destructive surgery was taken with written consent. Decapitation was only modality. It is an aggressive procedure and requires Blond-Heidler saw that was especially arranged for the procedure. Fetal decapitation fortunately could be easily done by a routine scalpel, possibly due to old IUFD, followed by breech extraction through a fundal rupture. A macerated IUFD, male fetus of 2.7 kg was delivered. The placenta was not found in uterine cavity and the cord was found already tied with a suture (history of expulsion of placenta confirmed with attendants); still the abdominal cavity was explored well. The uterus was exteriorized and around a 4- to 5-cm transverse fundal rupture was noticed near the right cornua of uterus (Fig. 3). It was repaired with polygalactin suture. Hemostasis was secured, drain placed *in situ*, and abdomen closed in layers. The baby was handed over to the attendant with the head sutured back to the trunk on humanitarian grounds. The patient stood the surgery well, with 2 units of PRBCs transfused. Antibiotic coverage and prolong catheter were kept in view of a prolonged and obstructed labor. Postoperative period was uneventful and discharged on the ninth day.

Outcome and Followup

Postoperatively the patient was managed with one unit blood transfusion and routine medication. Patient remained stable except for 150 mL serous discharge that continued in drain till the third postop day. She was discharged on postoperative day nine in healthy condition and anti D was also given. The patient was counseled regarding followup for contraception and precaution for next pregnancy and need of antenatal visits.

DIFFERENTIAL DIAGNOSIS: DIAGNOSTIC DILEMMA

Preoperative Diagnosis

On clinical assessment, the first diagnosis was any undiagnosed fetal mass? Especially sacrococcygeal teratoma? Neural tube defect that was obstructing the delivery of the fetus. Hence, the significance of mandatory anomaly scans were proved.

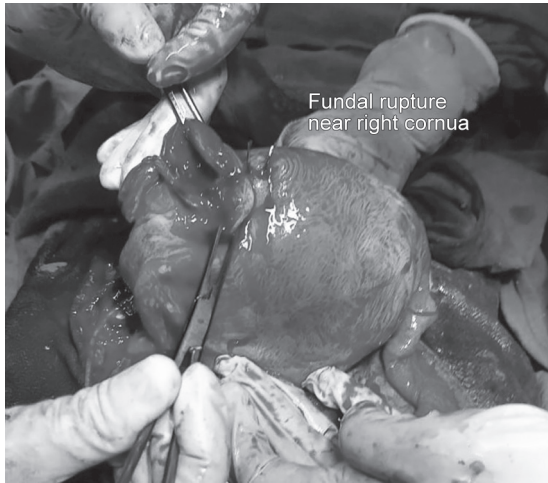


Fig. 3: After delivery of baby by decapitation, a fundal rupture of 4–5 cm was found near right cornua

The second suspicion of Bandl's ring was due to an obstructed labor because of a hour glass contour uterus per abdominally, upper abdomen appeared retracted (actually breech expelled through fundus), and lower abdomen distended (formed by uterus).

Final Diagnosis

Fundal rupture with breech expulsion secondary to obstructed labor due to injudicious use of oxytocin? Fundal pressure at PHCs? A result of poor assessment or malpractices?

DISCUSSION AND CONCLUSION

Obstructed labor is failure of descent of fetal presenting part despite good uterine contractions, hence leading to various maternal and fetal complications. The common causes are cephalopelvic disproportion, contracted pelvis (which seems the cause in this case), macrosomic baby, fetal malposition, fetal anomalies, tumors in ovary, uterus, vagina, etc.⁸ Rupture of uterus as a result of obstruction is life-threatening and difficult to diagnose especially in unscarred uterus primigravida (as in this case). There should be high index of suspicion in case of intractable abdominal pain in laboring women, which indicates uterine ischemic events and uterine rupture. Risk for uterine ruptures increases in multiparity, advanced age, low socioeconomic status, lack of antenatal care, uterine anomalies, induction and augmentation of labor, instrumentation, and attempted forceps delivery.⁹

In India, 70% is a rural population with a lack of better obstetric facilities and care.¹⁰ Proper antenatal care is either not available or not availed. Patients do not understand the importance of antenatal visits and many still prefer home deliveries by untrained female attendant/dais. Such patients usually report to nearby PHCs in case of complication such as obstructed labor or PPH, both being common reasons for maternal mortality. In India, 50% deliveries lack skilled or trained assistance.¹⁰ The patient is referred to higher centers from PHCs in inevitable last phase, which are often quite a distance away requiring more time. As in the present case, the patient was referred from a PHC at 160 km away from our tertiary center, which further increased the morbidity of the patient. These situations emphasize on the need to train the PHC doctors and staff in proper assessment of progress of labor and partograph with early referral before grave complications.

Secondly, PHC doctors should also be trained in performing destructive surgeries and judging situations where these are apt. Although obstructed labor is banished from the western world; hence, destructive operations are obsolete. In developing countries such as India, obstructed labor with dead fetus and severe infection is a sad reality, and destructive operations become an essential part and we consider that destructive operation still becomes necessary, especially in developing countries. The reported indices of fetal destructive operations vary between 0.2 and 1.6% deliveries.¹¹ In many situations, destructive surgeries should be preferred over a cesarean delivery, which needs much better facilities and greater morbidity. There is a great need for training PHC doctors by deputing a competent person from a teaching hospital to a PHC or *vice versa* on regular intervals.

CLINICAL SIGNIFICANCE/TAKE HOME MESSAGES

India is a developing country, we are taking many measures and have many programs to reduce maternal mortality and still birth, yet there is a lack of a proper maternal evaluation, assessment, and early referral facilities at the periphery level.

- Many patients do not understand the importance and necessity of proper antenatal visits, checkup, and institutional delivery.
- We should stress over judicious use of uterotonics especially oxytocin in labor with careful watch over contractions. Using partograph, pelvic assessment in active phase is key in early detection of obstructed labor.
- Practices such as fundal pressure should be prohibited.
- Had the patient reported early or referred early, maybe rupture uterus and stillbirth could be avoided.
- Obstetrics is unpredictable, every case is a new case, and no procedure can be obsolete in benefit of mother and baby. Destructive procedure can have a role even in modern obstetrics, especially in developing countries.
- PHC doctors should also be trained on regular intervals in assessment of labor progress, in performing destructive surgeries and judging situations and early referral before inevitable consequences.

PATIENT'S PERSPECTIVE

The patient agreed that she failed for antenatal checkups during her pregnancy. But she was happy that her life was saved with the grief of the loss of her baby.

ACKNOWLEDGMENT

Shalini Singh thank Prof Sudha Gandhi for her guidance and support. Thanks to junior residents for helping me in the follow-up and care of patient. Thanks to the patient and her family for being so cooperative throughout and hence helping us in our learning curriculum.

REFERENCES

1. Weeks A, Lavender T, Nazziwa E, et al. Personal accounts of "near-miss" maternal mortalities in Kampala, Uganda. *BJOG* 2005;112:1302–1307. DOI: 10.1111/j.1471-0528.2005.00703.x.
2. Beekle AT, McCabe C. Awareness and determinants of family planning practice in Jimma, Ethiopia. *Intl Nurs Rev* 2006;53:269–276. DOI: 10.1111/j.1466-7657.2006.00492.x.

3. Cron J. Lesson from the developing world: obstructed labor and the vesico-vaginal fistula. *Ob/Gyn and Women's Health. MedGenMed* 2003 Aug;5(3):24.
4. Hofmeyr GJ, Say L, Gulmezoglu A, et al. WHO systematic review of maternal mortality and morbidity: the prevalence of uterine rupture. *BJOG* 2005;112:1221–1228. DOI: 10.1111/j.1471-0528.2005.00725.x.
5. Zwart JJ, Richters JM, Ory F, et al. Uterine rupture in The Netherlands: a nationwide population-based cohort study. *BJOG* 2009;116(8): 1069–1078. DOI: 10.1111/j.1471-0528.2009.02136.x.
6. Gibbins KJ, Weber T, Holmgren CM, et al. Maternal and fetal morbidity associated with uterine rupture of the unscarred uterus. 2015 Sep;213(3):382. e1–382. e6. DOI: 10.1016/j.ajog.2015.05.048.
7. Al-Zirqi I, Kjersti Daltveit A, Forsén L, et al. Risk factors for complete uterine rupture. *Am J Obstet Gynecol* 2017;216:165.e1–165.e8.
8. Isalm JA, Ara G, Choudhury F. Risk factors and outcome of obstructed labour at tertiary care hospital. *J Shaheed Suhrawardy Med Coll* 2012;4(2):43–46. DOI: 10.3329/jssmc.v4i2.14401.
9. Abdulkadir T, Ali O, Evsen MS. Uterine rupture revisited: predisposing factors, clinical features, management and outcomes from a tertiary care center in Turkey. *Pak J Med Sci* 2013;29(3):753–757.
10. Parikh MN. Destructive operations in obstetrics. *J Obstet Gynecol India* 2006 Apr;56(2):113–114.
11. Okafor II. Neglected Obstructed Labor and the Need to Revive the “Dying Obstetric Art of Fetal Destructive Vaginal Operations” in the Developing Countries. *Ann Clin Case Rep* 2016;1:1049.