

Role of Prenatal Diagnosis in Parents with Sex Chromosomal Abnormality: A Review

Vineet V Mishra¹, Pritti K Priya², Priyankur Roy³, Hetvi Patel⁴

ABSTRACT

Sex chromosome aneuploidy is defined as a numeric abnormality of an X or Y chromosome and includes 45,X (Turner syndrome); 47,XXY (Klinefelter's syndrome); 47,XXX; and 47,XYY karyotypes. Individuals with 47,XXX and 47,XXY are generally fertile, but there is a risk of having a cytogenetically abnormal child in them. Turner and Klinefelter's syndromes are frequently associated with infertility, but few cases have been reported that they were able to give birth to a normal child as well as some children were born with similar or some other chromosomal abnormalities. Triple X syndrome occurs in 0.1% of live-born female newborns. Most of these newborns have a normal phenotype and only a few cases with 47,XXX karyotype have congenital malformations. These female patients may be mostly fertile, but there appears to be an increased risk of a cytogenetically abnormal child; the extent of this risk cannot yet be determined. Therefore, prenatal diagnosis and genetic analysis are therefore recommended. We report a rare case of triple X woman with a history of a Down syndrome child, for which she was advised a prenatal diagnosis in her subsequent pregnancy, and a review of other pertinent articles to establish the role of a prenatal diagnosis in parents with a sex chromosomal abnormality.

Keywords: Down syndrome, Klinefelter's syndrome, Prenatal diagnosis, Sex chromosome abnormality, Triple X syndrome, Turner syndrome.

Journal of South Asian Federation of Obstetrics and Gynaecology (2019); 10.5005/jp-journals-10006-1682

INTRODUCTION

Sex chromosome aneuploidy is the most common chromosome abnormality present at birth, with an overall incidence of 1 in 400, making it approximately twice as frequent in newborns as trisomy 21.¹ Autosomal abnormalities, such as trisomy 21, result in serious defects and a highly predictable severe prognosis for the fetus, sex chromosome aneuploidy is less damaging to the development of individuals, and its prognosis is far less predictable. Usually, sex chromosome aneuploidy is accidentally detected prenatally by amniocentesis or chorionic villus sampling conducted for other purposes. This completely unexpected result presents the parents with a very difficult personal decision whether to continue or terminate the pregnancy. On the other hand, to conduct genetic counseling in the case of sex chromosome aneuploidy is challenging as well, owing to the variability within each syndrome and the uncertain prognosis, especially in cases with mosaic karyotypes.

We hereby report an interesting case of triple X syndrome and hence will discuss triple X syndrome in brief. Triple X syndrome, also called trisomy X, is a genetic disorder that affects about 1 in 1,000 females. It is a sex chromosomal abnormality that involves the presence of three sex chromosomes resulting in 47,XXX karyotype.² The numerical abnormality occurs as a result of nondisjunction in meiosis I. Approximately 90% of these cases are of maternal origin and 10% of paternal origin. Postnatal diagnosis is difficult because most of these cases have a normal phenotype and do not manifest as a structural anomaly. Only a few cases with 47,XXX karyotype have congenital malformations reported in the literature.³ The fertility in females with 47,XXX karyotype may be normal; however, there appears to be an increased risk of a cytogenetically abnormal child; prenatal diagnosis is therefore advisable to rule out any chromosomal abnormality in the offspring and to help the parents by appropriate counseling.

¹⁻⁴Department of Obstetrics and Gynecology, GR Doshi and Smt KM Mehta Institute of Kidney Diseases and Research Centre, Dr HL Trivedi Institute of Transplantation Sciences (IKDRC-ITS), Ahmedabad, Gujarat, India

Corresponding Author: Pritti K Priya, Department of Obstetrics and Gynecology, GR Doshi and Smt KM Mehta Institute of Kidney Diseases and Research Centre, Dr HL Trivedi Institute of Transplantation Sciences (IKDRC-ITS), Ahmedabad, Gujarat, India, Phone: +91 9409302972, e-mail: preeti.ikdrc@gmail.com

How to cite this article: Mishra VV, Priya PK, Roy P, *et al.* Role of Prenatal Diagnosis in Parents with Sex Chromosomal Abnormality: A Review. *J South Asian Feder Obst Gynae* 2019;11(3):198–202.

Source of support: Nil

Conflict of interest: None

CASE DESCRIPTION

The couple was referred to us for secondary infertility along with a history of previous Down syndrome child. Parental karyotype was done. The karyotype of the female revealed XXX instead of two X chromosome and was reported as triple X (Fig. 1). The husband's karyotype was normal. The female was 23 years of age. Her height was 148 cm (<10th percentile) and weight was 37 kg (<10th percentile) (Fig. 2). She was phenotypically normal with good intelligence quotient (IQ). She had no developmental or behavioral problems. She gave a history of giving birth to a male child with Down syndrome two years back, who died on the ninth day after delivery. The child had typical features of Down syndrome, which was confirmed by karyotype, showing trisomy 21 (47,XY,+21).

She spontaneously conceived after a period of two years; prenatal diagnosis was advised. Amniocentesis was done at

18 weeks of gestation for genetic analysis. The karyotype of fetus was normal. She continued with the pregnancy and delivered a female baby at term without any complications. Both the mother and baby are doing well 2 months after delivery.

DISCUSSION

Many of these cases of sex chromosomal abnormality (SCA) are undiagnosed till late puberty or are diagnosed while undergoing investigations for infertility. Late diagnosis is because most of them are either asymptomatic or have less marked clinical features. For Turner females, primary amenorrhea is mainly the cause for investigation; for Klinefelter's, azoospermia remains the cause, but for XXX and XYY, there is no such specific feature for which they would be investigated (Table 1). Apart from abnormal psychological behavior, these conditions have been diagnosed retrospectively when a child is born to them with chromosomal abnormality. In our case, it was the birth of a Down syndrome child that led to parental karyotype and mother was revealed to have XXX.

There are a few cases that have been reported in the literature where parents with a sex chromosomal abnormality have given birth to a child with an abnormality as same as that of the parent or some other chromosomal abnormality with marked clinical findings. All these SCAs are usually not inherited, but occurs owing to a random event when the reproductive cells (eggs and sperm) are forming in the parent. Prenatal diagnosis is therefore required to give these parents an informed choice about their current pregnancy.

Pregnancies with a diagnosis of Turner's syndrome (45,X) and Klinefelter's syndrome (47,XXY) were terminated more often than pregnancies with a diagnosis of 47,XXX and 47,XYY. A study by Kim et al. showed that 60% of couples at their center continued pregnancy following a prenatal diagnosis of SCA except non-mosaic Turner syndrome.⁴ Most reports from other institutions also presented termination rates between 32% and 66%. Christian et al. reported that among the couples with normal fetal ultrasound findings, the overall continuation rate was 40%.⁵

This difference in choice for termination of pregnancy could be attributed to parental concern of having a child with abnormal sexual development or infertility, which are usually presented as parts of Turner or Klinefelter's syndromes but not of 47,XXX or 47,XYY karyotypes. Furthermore, Turner's and Klinefelter's



Fig. 1: Triple X female with normal phenotype

Table 1: Clinical features of various sex chromosomal abnormalities

<i>Sex chromosome abnormalities</i>			
<i>Genotype</i>	<i>Sex</i>	<i>Syndrome</i>	<i>Physical traits</i>
XXY, XXYY, XXXY	Male	Klinefelter's syndrome	Sterility, small testicles, breast enlargement
XYY	Male	XYY syndrome	Normal male traits
XO	Female	Turner's syndrome	Sex organs do not mature at adolescence, sterility, short stature
XXX	Female	Trisomy X	Tall stature, learning disabilities, limited fertility

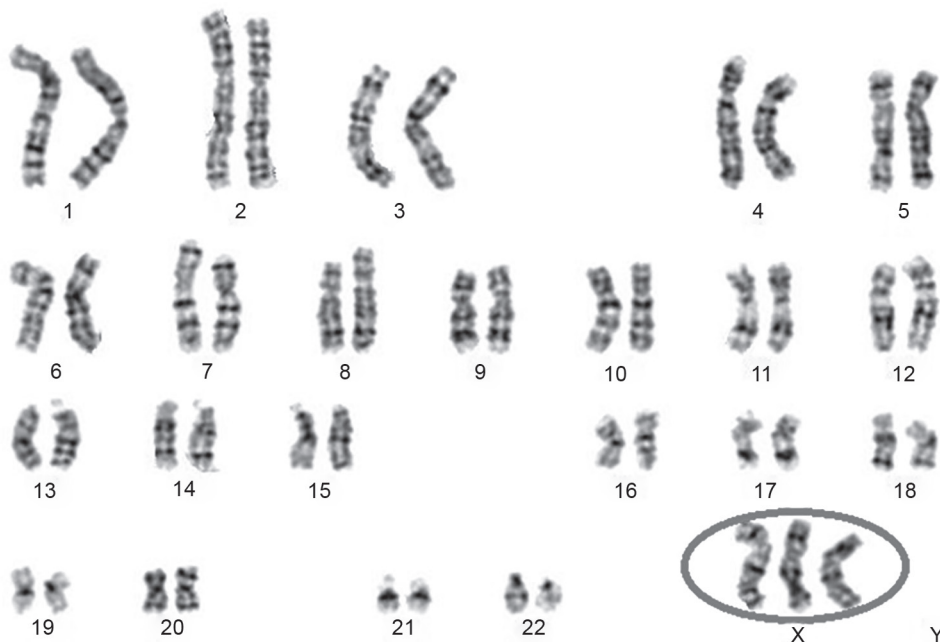


Fig. 2: Karyotype of the female showing 47,XXX

syndromes are frequently associated with clinical manifestations, including cardiac and kidney problems, gynecomastia, lack of secondary sexual characteristics, and reduced intelligence quotient, which might also be threatening for the parents.⁶ In contrast, individuals with 47,XXX and 47,XXY are often taller in stature but are not usually associated with other clinical manifestations.⁷⁻⁹

Triple X Syndrome

The first 47,XXX karyotype was described by Jacobs et al. in 1959 as the "super female," although in most cases these females with an extra X chromosome were identified in hospitals for the mentally subnormal.² Female infants with 47,XXX are relatively common, occurring in 0.1% of live born female infants.¹⁰ Most of these infants have a normal phenotype with a normal IQ. Only a few cases with 47,XXX karyotype have congenital malformations reported in the literature.^{3,11-13}

The unbalanced chromosome constitution in 47,XXX females creates some characteristic phenotypic features as an increase in height owing to an increased leg length, small head circumference, increased tooth enamel thickness, and reduced linear growth, and increased angles within the craniofacial complex.¹⁴ However, in our case, the female is of short height though her head circumference was small, contrary to previous reports in the literature. Individuals who are genetic mosaics (XX/XXX) have less noticeable symptoms.

In typical 46,XX females, only one X chromosome in each cell is genetically active and the other is inactivated.¹⁵ Approximately 5–10% of additional genes on the X chromosome outside the PAR regions escape X-inactivation along with pseudoautosomal regions (PAR1 and PAR2). The variable phenotypic abnormalities associated with trisomy X are thought to be related to the overexpression of the genes situated on the extra X chromosomes that escape X-inactivation.¹⁶

The present triple X female was drawn to our attention because of secondary infertility and a past history of giving birth to a child with the Down syndrome. There was nothing about this woman's physical appearance that would have indicated that she possessed an extra X chromosome. Thus, the karyotype of 47,XXX was an unexpected finding.

While fertility in women with trisomy X is generally considered normal, there is an increased risk for premature ovarian failure (POF), which may be important to consider in family planning. Furthermore, patients should be counseled that the transmission of X aneuploidy (extra or missing X chromosomes) from women with trisomy X is rare, although it has been reported.¹⁷ Although some reports support a <5% increased risk for chromosomally abnormal offspring,^{18,19} more recent figures support that <1% may be more accurate. It is important that this risk be presented independently of the risks due to maternal age. These transmission risks apply only to women with non-mosaic 47,XXX, as mosaicism may increase the risk of X aneuploidy and potential outcomes; so each scenario should be considered individually.¹⁸⁻²⁰ Singer et al. and El-Dahtory et al. have reported cases, where a Down syndrome child was born to an XXX female.²¹ Haverly et al. reported a case of a 47,XXX mother having had a 47,XXX daughter.²³ Though there are few cases reported, the risk for having aneuploid child could not be denied and therefore a prenatal diagnosis by genetic testing should be offered to these mothers.

To our knowledge, this is the first example of a triple X female giving birth to a child with Down syndrome in India. It would be of interest to speculate that there is a causal relationship in the fact that this triple X mother produced a trisomy-21 child.

Klinefelter's Syndrome

With an incidence of about 1 in 600 newborn boys, Klinefelter's syndrome is one of the most common sex chromosomal abnormalities in humans that affect male physical and cognitive development. The syndrome is the result of one additional X chromosome, or a 47,XXY karyotype. The extra X chromosome interferes with male sexual development, often preventing the testes from functioning normally and reducing the levels of testosterone.

Until 1996, men with Klinefelter's syndrome were considered infertile because they are usually associated with azoospermia or severe oligozoospermia. Current ART has advanced to the stage where the development of intracytoplasmic sperm injection (ICSI) has provided an effective therapy for severe male subfertility. Despite having a 47,XXY karyotype, indicating the presence of Klinefelter's syndrome, a patient's spermatozoa can be used to produce a clinical pregnancy. Thus, ICSI has offered XXY men an increased chance to father children.²⁴⁻²⁶ The mosaic forms of Klinefelter's syndrome, such as 46,XY/47,XXY, may have a viable sperm in their ejaculate and hence be able to father a child without ART.

The ICSI is associated with an increased risk of producing a chromosome anomaly in offspring.²⁷ IVF is also associated with an increased risk for *de novo* chromosomal aberrations, especially those involving the sex chromosomes.^{28,29} Therefore, in this era of assisted reproduction, where we have increased the chances of such parents having their biological offspring, the role of prenatal diagnosis has increased manifold.

Reproductive genetic counseling of patients with the 47,XXY karyotype remains difficult. Some authors have recommended pre-implantation or prenatal diagnosis after ICSI using sperm cells from patients with the 47,XXY karyotype.³⁰⁻³² Arguments from authors who propose a pre-implantation genetic diagnosis (PGD) include the increased risk of producing sex chromosomal—abnormal offspring (the unbalanced offsprings are 47,XXX or 47,XXY karyotypes).^{25,26,32-34}

Genetic counseling should be reassuring and management of the pregnancy should proceed with caution.³⁵

Turner's Syndrome

Turner syndrome is one of the most common sex chromosome abnormalities in females, and occurs in approximately 1 in 2,000 to 1 in 2,500 live female births, on the basis of epidemiological and newborn genetic screening data from Europe, Japan, and the United States.³⁶⁻³⁸

Most women with Turner's syndrome have ovarian dysgenesis; therefore, they are usually infertile and, in very rare cases, have spontaneous menses followed by early menopause. Only 2% of the women have natural pregnancies, with high rates of miscarriages, stillbirths, and malformed babies. Their pregnancy rate in oocyte donation programmes is 24–47%, but even these pregnancies have a high rate of miscarriage, probably due to uterine factors.³⁹

There are few cases reported in the literature where a mother with Turner syndrome has given birth to a child with Turner syndrome or its variants. Valera et al. reported a case where a woman with Turner syndrome having normal secondary sex characteristics became pregnant on two occasions. She had a 45,X karyotype in lymphocytes and skin fibroblasts. The first pregnancy ended in a miscarriage at 2 months of gestation. In the second pregnancy, cultured amniocytes showed a 46,X, del(X)(p21) karyotype. This pregnancy resulted in an apparently normal girl.⁴⁰

A girl with Turner's syndrome due to a 45,X mosaicism and a ring chromosome was born to a 29-year-old mother with a non-mosaic 45,X in her blood lymphocytes.⁴¹ Cools et al. reported a woman with a non-mosaic (45,X) form of Turner's syndrome who gave birth to a girl with 45,X Turner syndrome.⁴²

In the literature, girls with Turner's syndrome are said to have functional ovarian tissue and pregnancies in women with Turner's syndrome after oocyte donation and ICSI are no longer exceptional. However, since ovarian failure occurs relatively early during adolescence, cryopreservation of ovarian tissue containing immature follicles before the onset of early menopause should be considered as soon as the girl or her parents are able to make the necessary decisions.

Should these autologous oocytes indeed be used in the future, affected women would need to undergo genetic counselling before conception, followed by prenatal assessment. Besides the risks for congenital anomalies in the newborn, the risks of pregnancies in Turner's syndrome should not be neglected, as premature delivery due to disproportion between the pelvis and the fetus and aortic dissection in the pregnant woman are also known to occur.⁴³

CONCLUSION

Early knowledge of an SCA or any chromosomal aneuploidy could help the parents and their child to adapt to the consequences of the corresponding syndrome in a timely manner rather than having the information presented at puberty or even at a later stage in life. The couples should be informed with the most reliable and accurate information about the possible abnormalities, expected prognosis, and current and potential future treatment options; so they are able to make an informed decision about the pregnancy in accordance with their own values and to come to terms with their decision.

Genetic counseling for SCA females should address reproductive issues, specifically POF and the risk of transmission. The genetic risk in the offspring of patients with 47,XXY karyotype remains unknown but is presumably low. Prenatal diagnosis in parents with SCA has a definite role as there is an increased risk for chromosomal abnormality in their offspring.

REFERENCES

- Jacobs PA. The incidence and etiology of sex chromosome abnormalities in man. Robinson A, Lubs HA. Sex chromosome aneuploidy: prospective studies on children. New York (NY): A.R. Liss; 1979.
- Jacobs PA, Baikie AG, et al. Evidence for the existence of the human "super female". *Lancet* 1959;274:423–425. DOI: 10.1016/S0140-6736(59)90415-5.
- Khoury-Cotlado F, Wehbeh AN, et al. Prenatal diagnosis of 47,XXX. *Am J Obstet Gynecol* 2005;192:1469–1471. DOI: 10.1016/j.ajog.2004.12.037.
- Kim Y-J, Park S-Y, et al. Parental Decisions of Prenatally Detected Sex Chromosome Abnormality. *J Korean Med Sci* 2002;17:53–57. DOI: 10.3346/jkms.2002.17.1.53.
- Christian SM, Koehn D, et al. Parental decisions following prenatal diagnosis of sex chromosome abnormality: A trend over time. *Prenat Diagn* 2000;20:37–40. DOI: 10.1002/(SICI)1097-0223(200001)20:1<37::AID-PD748>3.0.CO;2-G.
- Petrucelli N, Walker M, et al. Continuation of pregnancy following the diagnosis of a fetal sex chromosome abnormality: A study of parents' counseling needs and experiences. *J Genet Counsel* 1998;7:401–415. DOI: 10.1023/A:1022828715158.
- Linden MG, Bender BG, et al. Intrauterine diagnosis of sex chromosome aneuploidy. *Obstet Gynecol* 1996;87:468–475. DOI: 10.1016/0029-7844(95)00419-X.
- Evans MI, Sobiecki MA, et al. Parental decisions to terminate/continue following abnormal cytogenetic prenatal diagnosis: "What" is still more important than "When". *Am J Med Genet* 1996;61:353–355. DOI: 10.1002/(SICI)1096-8628(19960202)61:4<353::AID-AJMG9>3.0.CO;2-V.
- Holmes-Siedle M, Ryyanen M, et al. Parental decisions regarding termination of pregnancy following prenatal detection of sex chromosome abnormality. *Prenat Diagn* 1987;7:239–244. DOI: 10.1002/pd.1970070403.
- Simpson JL, Elias S. Sex chromosomal polysomies (47,XXY; 47,XYY; 47,XXX), sex reversed (46,XX) males, and disorders of the male reproductive ducts. Simpson JL, Elias S. *Genetics in obstetrics and gynecology*. Philadelphia: Saunders; 2003. pp. 323–341.
- Jagadeesh S, Jabeen G, et al. Triple X syndrome with rare phenotypic presentation. *Indian J Pediatr* 2008;75:629–631. DOI: 10.1007/s12098-008-0120-8.
- Kim ES, Gross TL. Prenatal ultrasound detection of a congenital epulis in a triple X female fetus: A case report. *Prenat Diagn* 1999;19:774–776. DOI: 10.1002/(SICI)1097-0223(199908)19:8<774::AID-PD615>3.0.CO;2-7.
- Lin HJ, Ndiforchu F, et al. Exstrophy of the cloaca in a 47,XXX child: Review of genitourinary malformations in triple X patients. *Am J Med Genet* 1993;45:761–763. DOI: 10.1002/ajmg.1320450619.
- Robinson A, Lubs HA, et al. Summary of clinical findings: Profiles of children with 47,XXY, 47,XXX and 47,XYY karyotypes. *Birth Defects Orig Artic Ser* 1979;15(1):261–266.
- Ng K, Pullirsch D, et al. Xist and the order of silencing. *EMBO Rep* 2007;8(1):34–39. DOI: 10.1038/sj.embor.7400871.
- Tartaglia NR, Howel S, et al. A review of trisomy X (47,XXX). *Orphanet J Rare Dis* 2010;5:8. DOI: 10.1186/1750-1172-5-8.
- Hook E. Chromosome abnormalities: Prevalence, risks and recurrence. *Prenat Diagn Screen* 1992;351–392.
- Ratcliffe S. Long-term outcome in children of sex chromosome abnormalities. *Arch Dis Child* 1999;80(2):192–195. DOI: 10.1136/ad.80.2.192.
- Neri G. A possible explanation for the low incidence of gonosomal aneuploidy among the offspring of Triple X individuals. *Am J Med Genet* 1984;18(2):357–364. DOI: 10.1002/ajmg.1320180220.
- Dewhurst J. Fertility in 47,XXX and 45,X patients. *J Med Genet* 1978;15(2):132–135. DOI: 10.1136/jmg.15.2.132.
- Singer J, Sachdeva S, et al. Illinois, USA: Stritch School of Medicine, Loyola University. 2160 S. First Avenue, Maywood; 1972. p. 60153.
- El-Dahtory FAM. Triple X Egyptian woman and a Down's syndrome offspring. *Indian J Hum Genet* 2013;19(1):111–112. DOI: 10.4103/0971-6866.112925.
- Haverty CE, Lin AE, et al. 47,XXX associated with malformations. *Am J Med Genet* 2004;125:108–111. DOI: 10.1002/ajmg.a.20393.
- Tournayre H, Camus M, et al. Surgical sperm retrieval for intracytoplasmic sperm injection. *Int J Androl* 1997;20:69–73.
- Palermo G, Schlegel PN, et al. Birth after intracytoplasmic injection of sperm obtained by testicular extraction from men with non-mosaic Klinefelter's syndrome. *N Engl J Med* 1998;338:588–590. DOI: 10.1056/NEJM199802263380905.
- Ron-El R, Friedler S, et al. Birth of a healthy neonate following the intracytoplasmic injection of testicular spermatozoa from a patient with Klinefelter syndrome. *Hum Reprod* 1999;14:368–370. DOI: 10.1093/humrep/14.2.368.
- Aboulghar H, Aboulghar M, et al. A prospective controlled study of karyotyping for 430 consecutive babies conceived through intracytoplasmic sperm injection. *Fertil Steril* 2001;76(2):249–253. DOI: 10.1016/S0015-0282(01)01927-6.
- Van Opstal D, Los FJ, et al. Determination of the parent of origin in nine cases of prenatally detected chromosome aberrations found after intracytoplasmic sperm injection. *Hum Reprod* 1997;12(4):682–686. DOI: 10.1093/humrep/12.4.682.
- Bonduelle M, Aytöz A, et al. Incidence of chromosomal aberrations in children born after assisted reproduction through intracytoplasmic sperm injection. *Hum Reprod* 1998;13:781–782. DOI: 10.1093/humrep/13.4.781.

30. Staessen C, Coonen E, et al. Preimplantation diagnosis for X and Y normality in embryos from three Klinefelter patients. *Hum Reprod* 1996;11(8):1650–1653. DOI: 10.1093/oxfordjournals.humrep.a019463.
31. Reubinoff BE, Abeliovich D, et al. A birth in non-mosaic Klinefelter syndrome after testicular fine needle aspiration, intracytoplasmic sperm injection and preimplantation genetic diagnosis. *Hum Reprod* 1998;13(7):1887–1892. DOI: 10.1093/humrep/13.7.1887.
32. Rosenlund B, Hreinsson JG, et al. Birth of a healthy male after frozen thawed blastocyst transfer following intracytoplasmic injection of frozen thawed testicular spermatozoa from a man with non-mosaic Klinefelter syndrome. *J Assist Reprod Genet* 2002;19(3):149–151. DOI: 10.1023/A:1014792922874.
33. Hinney B, Guttenbach M, et al. Pregnancy after intracytoplasmic sperm injection with sperm from a man with a 47,XXY Klinefelter karyotype. *Fertil Steril* 1997;68(4):718–720. DOI: 10.1016/S0015-0282(97)00280-X.
34. Cruger D, Toft B, et al. Birth of a healthy girl after ICSI with ejaculated spermatozoa from a man with non-mosaic Klinefelter syndrome. *Hum Reprod* 2001;16(9):1909–1911. DOI: 10.1093/humrep/16.9.1909.
35. Tachdjian G, Frydman N, et al. Reproductive genetic counselling in non-mosaic 47,XXY patients: implications for preimplantation or prenatal diagnosis: Case report and review. *Hum Reprod* 2003;18(2):271–275. DOI: 10.1093/humrep/deg070.
36. Bondy CA. Turner Syndrome Study Group. Care of girls and women with Turner syndrome: A guideline of the Turner Syndrome Study Group. *J Clin Endocrinol Metab* 2007;92:10. DOI: 10.1210/jc.2006-1374.
37. Cockwell A, MacKenzie M, et al. A cytogenetic and molecular study of a series of 45,X fetuses and their parents. *J Med Genet* 1991;28:151. DOI: 10.1136/jmg.28.3.151.
38. Nielsen J, Wohlert M. Chromosome abnormalities found among 34,910 newborn children: results from a 13-year incidence study in Arhus, Denmark. *Hum Genet* 1991;87:81. DOI: 10.1007/BF01213097.
39. Abir R, Fisch B, et al. Turner's syndrome and fertility: current status and possible putative prospects. *Hum Reprod Update* 2001;7(6):603–610. DOI: 10.1093/humupd/7.6.603.
40. Varela M, Shapira E, et al. Ullrich-Turner syndrome in mother and daughter: Prenatal diagnosis of a 46, X, del(X)(p21) offspring from a 45,X mother with low-level mosaicism for the del(X)(p21) in one ovary. *Am J Med* 1991;39(4):411–412. DOI: 10.1002/ajmg.1320390409.
41. Blumenthal AL, Allanson JE. Turner syndrome in a mother and daughter: r(X) and fertility. *Clin Genet* 1997;52:187–191. DOI: 10.1111/j.1399-0004.1997.tb02543.x.
42. Martine C, Raoul PA, et al. A mother and daughter with 45,X karyotype. *Fertil Steril* 2004;82(4):923–925. DOI: 10.1016/j.fertnstert.2004.02.129.
43. Waelkens JJ. Turner's syndrome in mother and daughter. *Ned Tijdschr Geneeskd* 2004;148(24):1208–1210.