

## CASE REPORT

# Oophorexy and Ovarian Bivalving in Recurrent Ovarian Torsion in Premenarchial Patient: Review of the Technique

<sup>1</sup>Dipak Limbachiya, <sup>2</sup>Heena Chawla, <sup>3</sup>Preeti Gandhi, <sup>4</sup>Abeer Alzaydai

## ABSTRACT

Oophorexy for ovarian torsion is a simple procedure which seems justifiable in order to avoid devastating consequences. In premenarchial girls, pexy of the untwisted ovary, the contralateral ovary or both should be considered. We present an interesting case of 9-year-old girl with recurrent left ovarian torsion. This was the third episode of left ovarian torsion. She underwent right oophorectomy in the past for right ovarian torsion. Oophorexy along with detorsion had been done twice before with no success. So, during her third episode of left ovarian torsion ovarian bivalving after detorsion along with oophoropexy with multiple ligament fixations was done. After the untwisting of ischemic adnexa, ovarian bivalving is an effective technique to decrease ovarian intracapsular pressure, increase arterial perfusion, and facilitate adnexal reperfusion and recovery. As ovarian torsion may recur after detorsion unilateral or bilateral oophoropexy with multiple ligament fixations along with ovarian bivalving following detorsion may be performed to prevent recurrence.

**Keywords:** Adolescent girls, Ovarian bivalving, Ovarian fixation, Ovarian torsion.

**How to cite this article:** Limbachiya D, Chawla H, Gandhi P, Alzaydai A. Oophorexy and Ovarian Bivalving in Recurrent Ovarian Torsion in Premenarchial Patient: Review of the Technique. *J South Asian Feder Obst Gynae* 2018;10(4):273-275.

**Source of support:** Nil

**Conflict of interest:** None

**Date of received:** 05-07-2018

**Date of acceptance:** 25-12-2018

**Date of publication:** March 2019

## AIM

Oophoropexy for ovarian torsion is a simple procedure which seems justifiable in order to avoid devastating consequences. As ovarian torsion may recur after detorsion unilateral or bilateral oophoropexy with multiple ligament fixations along with ovarian bivalving following detorsion may be performed to prevent recurrence

## BACKGROUND

Torsion of the ovary, tube or both is responsible for 2.7–7.4% of all gynaecological emergencies but is a common diagnostic challenge in the emergency setting.<sup>1</sup> The ovary rotates around the infundibulopelvic and ovarian ligament interfering with its blood supply, which may be partial or complete. Ovarian torsion develops mostly due to ovarian mass or cyst, or prior pelvic surgery in women of reproductive age. The frequent presenting symptoms are acute onset of pelvic pain, nausea, vomiting, fever, and adnexal mass with or without abnormal genital tract bleeding. Delay or misdiagnosis can result in the loss of the affected ovary and subsequent reduced reproductive function. However, diagnosis can be difficult, particularly in intermittent torsion. Pelvic ultrasound is still the first-line imaging study for diagnosing a patient with suspected ovarian torsion. Diminished or absent ovarian vessel flow on two-dimensional, color, and three-dimensional (3D) Doppler ultrasound has been proposed as a test for ovarian torsion.<sup>2</sup> Management should be conservative and ovarian preservation is required whenever possible, especially in young or infertility patients.<sup>3</sup> The conservative management consists of detorsion of the ovary followed by cystectomy if a mass is present. Detorsion and oophoropexy, rather than oophorectomy, are surgical techniques that are increasing in popularity.

Newer techniques to prevent recurrence, such as shortening of the utero-ovarian ligament are also being performed but require further study to support its validity.<sup>4</sup>

## CASE DESCRIPTION

A 9-year-old girl with history of recurrent left ovarian torsion and right oophorectomy (previous three laparoscopies) presented to us with complaint of left-sided

<sup>1</sup>Director, <sup>2-4</sup>Consultant

<sup>1</sup>Department of Obstetrics and Gynaecology, Eva Womens Hospital, Ahmedabad, Gujarat, India

<sup>2</sup>Department of Gynaecology, Laparoscopy and Oncology, Apollo Clinic, Chandigarh, India

<sup>3</sup>Department of Obstetrics and Gynaecology, National Health Service, Scunthorpe, Northern Lincolnshire, UK

<sup>4</sup>Department of Obstetrics and Gynaecology, Al Jahra Health District Hospital, Alsafat, Al Jahra, State of Kuwait

**Corresponding Author:** Heena Chawla, Consultant, Department of Gynaecology, Laparoscopy and Oncology, Apollo Clinic, Chandigarh, India, e-mail: heena8240@rediffmail.com

lower abdominal pain and vomiting since 6 hours. Ultrasound was done at our centre which showed significantly enlarged left ovary measuring 55 × 60 × 47 mm (vol 78 cc). There were multiple peripherally arranged follicles with antral echogenic stroma. Color Doppler showed minimum internal vascularity suggestive of ovarian torsion. Right ovary was not seen (in view of oophorectomy). This patient had a history of laparoscopic right sided oophorectomy one and a half year back due to right ovarian torsion operated outside. Six months after right oophorectomy, she again presented with lower pain abdomen and vomiting at our center. Ultrasound showed left ovarian volume 25 cc and color Doppler suggested left ovarian torsion. Surgery was planned and laparoscopic left sided ovarian detorsion with ovarian fixation was done. Ovarian fixation was performed using two interrupted sutures were taken with vicryl 1-0 between left ovary and left lateral pelvic wall. Follow-up ultrasound done three weeks after surgery showed normal vascularity. To our surprise, four months later she again presented with excruciating pain abdomen with nausea, vomiting since one day. Ultrasound findings with Doppler were again suggestive of left ovarian torsion. Hence, laparoscopic left sided ovarian detorsion with oopho-

ropexy was done outside. Two interrupted sutures were taken with prolene 1-0 between ovary and lateral pelvic wall. Follow-up color Doppler done 3 weeks later again showed normal vascularity. Our patient presented few months later at our centre with the same complaints and diagnosis of recurrent third left ovarian torsion was made. Intraoperatively, left ovary was enlarged measuring 6 × 8 cm, congested, studded with hemorrhagic patches, twisted into 4 turns over the ovarian ligament, left tube was tortuous and elongated. Detorsion of the left ovary was done. Incision was given by scissors over the most dependable portion of left ovary and healthy ovarian tissue was seen (ovarian bivalving) as depicted in Figure 1. After delineation of ureter, fixation of left ovary was performed using prolene 1-0 by 4 interrupted sutures. Three sutures were taken with the peritoneum of the lateral pelvic wall and one interrupted suture was taken with the posterior surface of the uterus as shown in Figure 2. Fixation of the left fallopian tube to the left lateral pelvic wall was done by prolene 3-0 suture and four interrupted sutures were taken. Figure 3 depicts the fixation of left fallopian tube to lateral pelvic wall. Follow-up color Doppler done three weeks after surgery demonstrated normal vascularity.

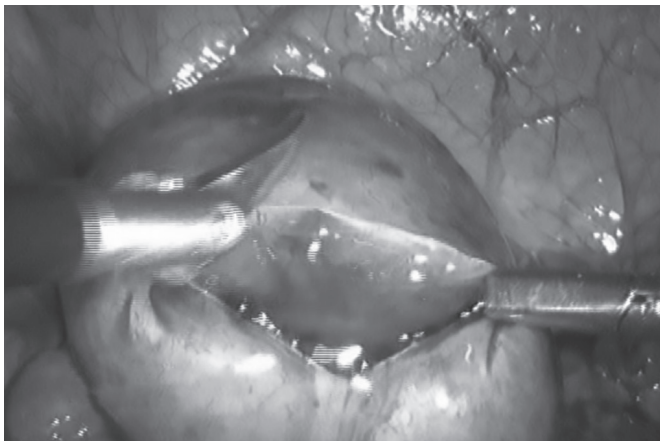


Fig. 1: Ovarian bivalving

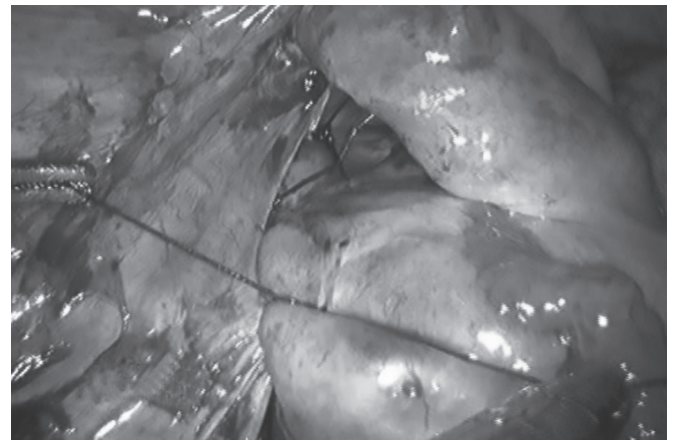


Fig. 2: Depicting fixation of left ovary to lateral pelvic wall

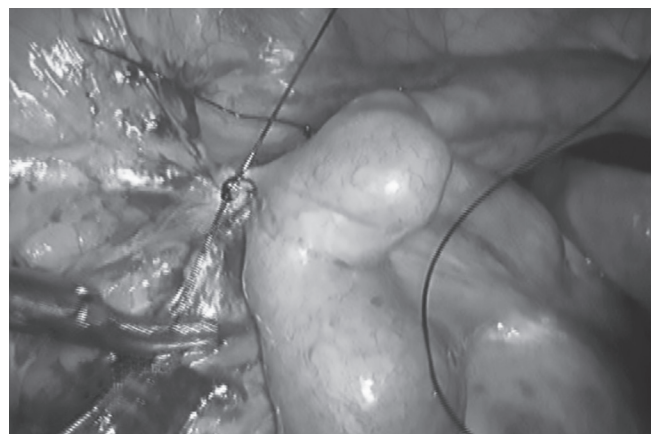


Fig. 3: Fixation of left fallopian tube to lateral pelvic wall

**DISCUSSION**

Torsion can also occur in normal ovaries, however, particularly in premenarchal girls who have elongated infundibulopelvic ligaments. Surgical management of adnexal torsion is determined by many factors including macroscopic appearance of the adnexum, age, menopausal status, presence of preexisting ovarian pathology and desire to preserve fertility. Traditionally, surgery has involved partial or complete oophorectomy or salpingo-oophorectomy. There are good outcome data to support conservative management with laparoscopic detorsion in the majority of cases with little short or long-term associated morbidity, even if the ovary appears dark purple or black.<sup>5</sup> Postoperative follow-up with ultrasound show over 80% of patients had normal follicular development after detorsion. In addition, outcomes from pediatric cases of torsion would support a more conservative approach to surgical management in the form of detorsion with or without oophoropexy.<sup>6</sup>

Although oophoropexy for ovarian torsion is debatable situation, retorsion may occur. Oophoropexy for ovarian torsion is emergency procedure, if we compare the most accepted way of oophoropexy by ovarian ligament fixation.<sup>7</sup> In first episode, only right ovarian torsion was observed and oophorectomy was done. There is evidence to suggest that the clinical appearances of torted adnexae do not correlate well with the likelihood of residual ovarian function and recovery. Whether fixation should have been done for the left ovary at the time is still debatable. In the second episode, left ovarian torsion was found and detorsion and oophoropexy with absorbable sutures was performed. In the third episode again left ovarian torsion was diagnosed and detorsion with oophorexy with non absorbable sutures done. In the fourth episode, third time left ovarian torsion was diagnosed and this was the third episode on the left side. Laparoscopic de torsion of left ovary with ovarian bivalving and fixation of left ovary along with fallopian tube with nonabsorbable sutures was done.

Whether or not to perform oophoropexy of normal adnexae when detorsion is performed is less clear. In cases where recurrent torsion has occurred, oophoropexy has been shown to be effective in reducing the recurrence rate. There are case reports in the literature of fixing the detorted ovary, or contralateral ovary, to the back of the uterus, or shortening of the uteroovarian ligament. The aim of oophorexy should be to shorten ligament length, add additional support directions while avoiding vital structures.<sup>8</sup> Shortening a single ligament length with nonabsorbable suture or delayed absorbable suture is the most commonly technique used as was done in our

previous two oophorexies. Additional benefit may be obtained by using multiple ligaments with opposing angles thus providing fewer angles for articulations so that ovary cannot rotate as was done in the third laparoscopic oophorexy. We also advocate bivalving the ovary following untwisting in the case of severely hemorrhagic and edematous adnexa. As was performed in our patient, a linear incision was made along the antimesenteric aspect of the affected ovary after untwisting. This method serves to confirm viable tissue within hemorrhagic, ischemic areas, and releases the increased pressure of the edematous ovarian capsule to facilitate lymphatic and venous drainage and allow adequate arterial flow. Laparoscopic approach would be the preferred route in order to reduce admission time, postoperative pain and long-term risk of adhesion formation. These reports are mainly in children and adolescents, however, long-term outcomes in these cases are unclear. However, it has been one year since the last detorsion of this patient and she has attained spontaneous menarche six months after the last surgery. We hypothesize that the cause of recurrent ovarian torsion was related to hypermobility of adnexal structures.

**CONCLUSION**

Although shortening of the utero-ovarian ligament and oophoropexy can be performed for prevention of further episodes of ovarian torsion, possible occurrence of recurrence must be kept in mind in these patients. Future research studies are needed to assess if there is a superior technique of oophorexy that has lower recurrence rate.

**REFERENCES**

1. Hibbard LT Adnexal Torsion. *Am J Obstet Gynecol* 1985;152:456-461.
2. Anthony EY, Caserta MP, Singh J, Chen MY. Adnexal masses in female pediatric patients. *American Journal of Roentgenology*. 2012 May;198(5):W426-431.
3. Weitzman VN, DiLuigi AJ, Maier DB, Nulsen JC. Prevention of recurrent adnexal torsion. *Fertility and Sterility*. 2008 Nov 1;90(5):2018-e1.
4. Damigos E, Johns J, Ross J. An update on the diagnosis and management of ovarian torsion. *The Obstetrician & Gynaecologist* 2012;14:229-236.
5. Oelsner G, Bider D, Goldenberg M, Admon D, Mashiach S. Long-term follow-up of the twisted ischemic adnexa managed by detorsion. *Fertility and Sterility*. 1993 Dec 1;60(6):976-979.
6. Breech LL, Hillard PJ. Adnexal torsion in paediatric and adolescent girls. *Curr Opin Obstet Gynecol* 2005;17:483-489.
7. Pansky M, Smorgick N, Herman A, Schneider D, Halperin R. Torsion of normal adnexa in postmenarchal women and risk of recurrence. *Obstetrics & Gynecology*. 2007 Feb 1;109(2):355-359.
8. Crouch NS, Gyampoh B, Cutner AS, Creighton S. Ovarian torsion: to pex or not to pex? *J Paediatr Adolesc Gynecol* 2003;16:381-384.