

# Clinical Manifestations and Challenges in Management of Tuberculosis in Pregnancy in a Rural Setting in Eastern India

<sup>1</sup>Mallika Sengupta, <sup>2</sup>Anirban Dasgupta, <sup>3</sup>Debjyoti Santra, <sup>4</sup>Pulok K Jana, <sup>5</sup>Subhendu Dasgupta

## ABSTRACT

**Aim:** To observe fetomaternal outcomes of both pulmonary and extrapulmonary tuberculosis (TB) in pregnancy as well as effects of pregnancy on TB.

**Materials and methods:** Antenatal patients with history of chronic cough, expectoration, and weight loss were enrolled and included from antenatal, chest medicine, medicine outpatients as well as from obstetric emergency and labor wards. Detailed history, examination, sputum for acid-fast bacilli (AFB), and culture were used to diagnose, and additional investigations, such as cassette-based nucleic acid amplification test (CBNAAT), Mantoux, chest X-ray, and computed tomography (CT)/magnetic resonance imaging (MRI) according to indications were used. Affected patients received antitubercular treatment (ATT) according to Revised National Tuberculosis Control Program (RNTCP) guidelines. Maternal weight gain in pregnancy, time and mode of delivery, fetal prematurity, growth restriction, and medical complications in pregnancy were chief parameters observed.

**Results:** A total of 14 patients were diagnosed with TB in pregnancy over 18 months from August 2015 to January 2017. Women who booked early in pregnancy had better weight gain, later gestation of delivery (38 vs 35 weeks), higher fetal birth weights (2,745 vs 1,835 gm) at delivery than those who booked late. Among the patients who booked late, one developed TB pericarditis, one had central nervous system (CNS) tuberculoma, and another lady died due to fatal pulmonary embolism from deep vein thrombosis (DVT) due to immobility. One of the preterm babies had congenital TB.

**Conclusion:** Tuberculosis, particularly extrapulmonary and presenting in advanced pregnancy, can be confused and missed, leading sometimes to catastrophic consequences.

**Clinical significance:** Pulmonary TB detected early and treated has an uneventful course in pregnancy. Any duration of TB treatment in pregnancy and postnatally should be accompanied with thromboprophylaxis, if immobility is present.

**Keywords:** Acid-fast bacilli, Antitubercular treatment, Pregnancy, Revised National Tuberculosis Control Program, Thromboprophylaxis, Tuberculosis.

**How to cite this article:** Sengupta M, Dasgupta A, Santra D, Jana PK, Dasgupta S. Clinical Manifestations and Challenges in Management of Tuberculosis in Pregnancy in a Rural Setting in Eastern India. *J South Asian Feder Obst Gynae* 2018;10(1): 15-22.

**Date of received:** 15 January 2018

**Date of acceptance:** 25 February 2018

**Date of publication:** May 2018

**Source of support:** Nil

**Conflict of interest:** None

## INTRODUCTION

Tuberculosis is one of the top 10 causes of death worldwide and, in 2015 alone, 10.4 million people fell ill worldwide with 1.8 million succumbing to TB, and this included 0.4 million who also had human immunodeficiency virus (HIV). About 95% of these deaths occurred in low socioeconomic countries with 6 countries contributing to 60% of these, India heading the list (4.8 lakh deaths).<sup>1</sup> The estimated incidence figure in 2015 is 2.8 million TB cases in India alone (25% of global figures).<sup>2</sup> A staggering 40% of the Indian population is affected by TB bacteria, most of them being latent TB rather than active TB infection. The global and Indian incidence of HIV-TB are 11.7 and 1.1 lakhs respectively, while that of multidrug resistant (MDR) TB globally and in India are 4.8 and 1.4 lakhs respectively (TB INDIA 2017 RNTCP annual status report).

However, TB remains a treatable and curable disease and "End TB Strategy"<sup>3</sup> adopted by World Health Organization in May 2014 outlines global impact targets to reduce TB deaths by 90%, cut new cases by 80% between 2015 and 2030, and ensure that no family is burdened with catastrophic costs due to TB. Tuberculosis also results in a sixfold increase in perinatal mortality and twofold rise in premature births and low birth weight babies.<sup>12</sup>

<sup>1</sup>Senior Resident, <sup>2</sup>Clinical Tutor, <sup>3</sup>Associate Professor  
<sup>4,5</sup>Professor and Head

<sup>1</sup>Department of Microbiology, ESIC Medical College & Hospital  
Kolkata, West Bengal, India

<sup>2,3,5</sup>Department of Obstetrics & Gynaecology, Bankura  
Sammilani Medical College & Hospital, Bankura, West Bengal  
India

<sup>4</sup>Department of Pulmonary Medicine, Bankura Sammilani  
Medical College & Hospital, Bankura, West Bengal, India

**Corresponding Author:** Anirban Dasgupta, Clinical Tutor  
Department of Obstetrics & Gynaecology, Bankura Sammilani  
Medical College & Hospital, Bankura, West Bengal, India  
Phone: +918056461564, e-mail: dr.anirbandasgupta@gmail.  
com

In women living with HIV as well, the risk of maternal and infant mortality rises by 300%. Also, evidence from India, in fact, showed that TB in mothers with HIV nearly doubled the risk of vertical transmission of HIV to the unborn child. Facility-based studies in a number of high HIV burden settings found TB accounted for 15 to 34% of indirect causes of obstetric mortality. Newer modalities like CBNAAT and line probe assays that help further in the diagnosis of MDR-TB along with smears have been introduced in several designated microscopy centers and culture and drug sensitivity test centers in districts like ours across the country.<sup>2</sup> A new drug called Belaquidine has been introduced in six pilot centers across the country for MDR cases, but there is as yet no use in pregnancy.

Tuberculosis is not rare in rural areas like Bankura,<sup>4</sup> where poor patient awareness results in late detection and poor compliance. Newly diagnosed TB in pregnancy can lead to miscarriage, medical termination of pregnancy due to unfounded maternal concerns, poor maternal weight gain in pregnancy, preterm delivery, and growth restriction of the fetus.

## MATERIALS AND METHODS

This was a prospective longitudinal observation study that we undertook in our institute over a period of 18 months from August 2015 to January 2017. Institute ethics committee clearance was obtained. Pregnant women in the age group 18 to 40 years in all trimesters were recruited from Obstetrics and Gynaecology, Chest Medicine outpatient departments (OPDs) as well as those presenting in Emergency Department with a history of chronic cough, night sweat, recent onset weight loss; for evaluating maternal and fetal outcomes over a period of 1 to 2 years. They were evaluated prospectively for the aforementioned symptoms including investigations, such as on sputum for AFB (Ziehl-Neelsen staining) and chest X-ray particularly for those with clinically advanced pulmonary disease, after informing them that the radiation dosage of <math><0.01\text{ mGy}</math> is safe in pregnancy, Gene-Xpert/CBNAAT, and further multidisciplinary work-up involving microbiology and respiratory medicine experts in our team after informed consent.

Affected patients were enrolled under the RNTCP-Directly Observed Treatment, Short-course (RNTCP-DOTS) program and received ATT as well as regular antenatal obstetric check-ups in the OPD with special emphasis on fetal and maternal clinical, biochemical, and ultrasound monitoring. Antenatal, intrapartum, and postnatal outcomes of TB in pregnancy were studied along with effects of pregnancy on the course of TB (remission/stable disease/flare up). Any rare diagnoses of congenital TB (Cantwell's criteria) and neonatal TB and their neonatal management were also studied in late

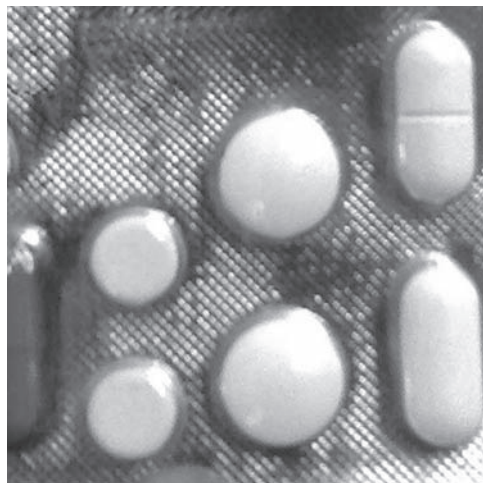

Fig. 1: Intensive phase blister pack

presenting women.

For patients with suggestive constitutional symptoms of pulmonary TB, two sputum samples were sent for microscopy in accordance with the RNTCP guidelines. For both sputum-negative cases, a 10- to 14-day course of antibiotics like amoxicillin was prescribed. Those with positive smears were started on thrice-weekly DOTS intensive phase (IP) incorporating 600 mg isoniazid, 450 mg rifampicin, 1,500 mg pyrazinamide, and 1,200 mg ethambutol for at least 2 months (Fig. 1). Those who tested sputum positive after 2 months of IP were continued on IP for a further 1 month and sputum reexamined after this extension.

Irrespective of the result of sputum test after extension of IP or when sputum-negative after IP, a consolidation phase (CP) of 4 months of isoniazid and rifampicin was given for all newly positive pulmonary/extrapulmonary cases. Recently, in March 2017, updated RNTCP guidelines have also incorporated ethambutol in CP. Protocol was changed for previously treated patients according to RNTCP guidelines in consultation with chest physician. A MDR-TB patient was defined as one who is culture-positive for TB, but resistant *in vitro* to isoniazid and rifampicin, while extensively drug-resistant (XDR) TB patients were those who alongside the above criteria for MDR were also resistant to a fluoroquinolone and a second line injectable (like kanamycin, capreomycin, etc.) according to drug resistance studies.

The regime of 6 months ATT was extended for extrapulmonary disease like bone disease, pericarditis (9 months), and CNS (12 months). The MDR and XDR patients were to be administered second-line chemotherapy according to RNTCP algorithms.

## COMPLIANCE WITH ETHICAL STANDARDS

No animals were used during this study. All observations done in this report are on humans and are in accordance

with the ethical guidelines of the Institute's Research Committee and in compliance with the 1964 Helsinki declaration and its later amendments and ethical standards. Informed consent was obtained from the participants involved in this study in their own language.

## RESULTS

A total of 14 patients in the age group 18 to 32 years were diagnosed with TB in pregnancy over 18 months from August 2015 to January 2017, out of the 104 patients who were investigated with chronic cough of at least 3 months duration. One patient had HIV coexistent with TB and, hence, was excluded, as antiretroviral drug therapy and HIV have their own effects on pregnancy and would have confounded our observations. Nine patients presented in first trimester with varying presentations (Table 1), one in second trimester, two in third trimester, and one postnatally. None of them were MDR. Ten of them were sputum-positive, while three were negative, as they were already on chemotherapy.

The mean body weight of the 13 patients in their first visit was  $45.833 \pm 13.53$  kg with a mean body mass index (BMI) of  $21.245 \pm 3.432$ , which was less than the mean booking BMI of 24 in our baseline pregnant population in antenatal clinics. The four women who came early in first trimester (Table 1) and delivered at-term had comparatively better socio-economic status and higher mean booking BMI of  $23.01 \pm 2.62$  (comparable with baseline booking BMI) reflecting better nutritional status in pregnancy. Overall, eight women had pregnancy continuing

beyond 28 weeks, while five had miscarriage of which only one was spontaneous, while four of them underwent termination of pregnancy having been started on abortifacients outside by general practitioners and presented having partially expelled products of conception. The mean booking hemoglobin (Hb) level for the nine patients presenting in the first trimester was  $9.8 \pm 2.3$  gm%, and was surprisingly comparable with the four patients presenting in second, third trimesters and postnatal period ( $9.83 \pm 2.16$  gm%), probably due to the skewing effect of high Hb value (12 gm%) in the lady presenting in the third trimester and going on to develop DVT.

Of the eight women who delivered, the mean gestational age and baby weight at delivery were 36.14 weeks (none were postdated and only one had a cesarean section due to fetal distress) and  $2,290 \pm 587$  gm, but for the four patients who presented in first trimester, the corresponding figures were significantly higher at 38 weeks and were  $2,745 \pm 241$  gm respectively. They had a mean pregnancy weight gain of 11.25 kg, and liver enzymes were raised in only one lady suggesting safety and efficacy of early start of ATT in pregnancy. The three women who presented in second and third trimesters delivered prematurely at 36, 32, and 34 weeks respectively, and along with the patient with pericarditis had a mean fetal birth weight of  $1,835 \pm 441$  gm. They had none or minimal pregnancy weight gain and, in fact, had a weight loss of 2.5 kg in the third trimester. Four babies were growth restricted, which included these three preterm babies [one neonate of 1,300 gm died in special newborn care unit (SNCU)] as well as a 2,242 gm baby born to a mother who delivered outside at 39 weeks

**Table 1:** Patient profile

Trimester of first visit	Number	Month and season	Parity	Presentation	Sputum positive	Pregnancy outcome
9 patients in first trimester	3 referred from chest outpatient 1 in gynec outpatient following infertility treatment and TB endometritis 5 patients	Dec–Jan	2 primigravida, 2 multi	3 presented with chronic cough; unclear about whether pregnancy can be continued, one with old evidence of TB salpingitis	3 out of 4	All delivered at term
		Jan–Mar	3 multi and 2 primigravidas	4 patients had consumed MTP medications/ abortifacients while one lady presented with spontaneous incomplete miscarriage	4 smear+ One smear negative on ATT	Miscarriage in 2, 2 underwent surgical evacuation, and 1 pregnancy continued to term
1 patient in 2nd trimester	Came at 24 weeks to obs/gynec emergency room	Feb–Mar	Multi	CNS TB mimicking early-onset eclampsia	Yes	Delivered near term
2 patients in 3rd trimester	At 32 and 34 weeks respectively	Dec–Jan	Both primi	Chronic cough and emaciated, presented with respiratory compromise. One had DVT and died postnatally due to pulmonary embolism	Both sputum smear 3+	Preterm, growth restricted babies, one had congenital TB. Other died postnatal
1 patient postnatal	7 days postnatal with dyspnea in gynec emergency	Feb	First baby	Tuberculosis pericarditis mimicking peripartum cardiomyopathy	No	Recovery

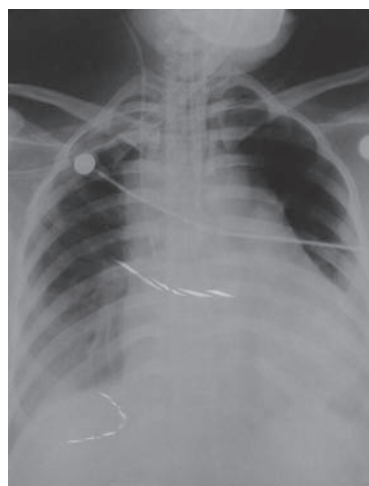


and was admitted here postnatally for pericarditis.

Persistent cough was the most common symptom noted among patients with pulmonary TB, while breathlessness was a late feature and sign of more advanced disease. Chest pain and wheeze were rare findings. The following scenarios describe the four patients who presented with advanced disease and they reemphasize the fact that TB remains a great mimicker of other medical disorders. Detailed history taking, sometimes with leading questions, where there is a high index of suspicion, may help in saving lives as in the following near miss.

**SCENARIO 1:** A 23-year-old lady P<sub>1</sub>L<sub>1</sub> having delivered 2 weeks back presented with increasing shortness of breath for 5 to 7 days and altered sensorium for a day. She had a history of fever 1 month back, but no other significant past medical/surgical history. She was pale on examination with cold clammy extremities with pedal edema, abdominal distension that was tympanitic on percussion. Her blood pressure (BP) was 90/60 mm Hg and pulse rate: 110/min with peripheral capillary oxygen saturation: 89% and respiratory rate: 30/min. The cardiovascular system examination: S<sub>3</sub> gallop+ but no murmurs. There was presence of Kussmaul's sign with elevation of jugular venous pulse with inspiration. Precordial examination suggested shifting of apex beat laterally with dullness on percussion lateral to apex beat. She was in a state of stupor with only response to pain. Baseline hemogram, urea, electrolytes, liver function test (LFT), electrocardiogram (ECG), and echocardiogram (ECHO) were done, while a bedside random blood sugar of 112 mg/dL was noted. She had a sudden cardiac arrest 1 hour after admission and was instituted cardiopulmonary resuscitation after intubation with 30:2 chest compressions with bag-valve-mask ventilation in accordance with advanced life support protocols, and intravenous adrenaline given. She could be revived, but BP had to be maintained by dobutamine support.

After initial stabilization, an ultrasonography (USG) was done, which was suggestive of hepatosplenomegaly and moderate pleural effusion; that was further corroborated by the chest X-ray that also revealed an enlarged heart (Fig. 2). The ECG had low voltage sinus tachycardia with T-wave inversion in few leads. The ECHO was done with suspicion of peripartum cardiomyopathy leading to congestive heart failure/pulmonary embolism, but surprisingly this was suggestive of moderate pericardial effusion without features of tamponade. Ejection fraction was reduced to 60% mimicking a cardiomyopathy and there was mild tricuspid regurgitation as well. A pericardiocentesis was performed and the fluid was sent for cell count/type, protein/sugar/lactose dehydrogenase (LDH), adenosine deaminase (ADA), and AFB smear and culture were also planned. The AFB smear was 1+, while pericardial fluid was exudative, pale yellow with



**Fig. 2:** Tuberculosis pericardial effusion

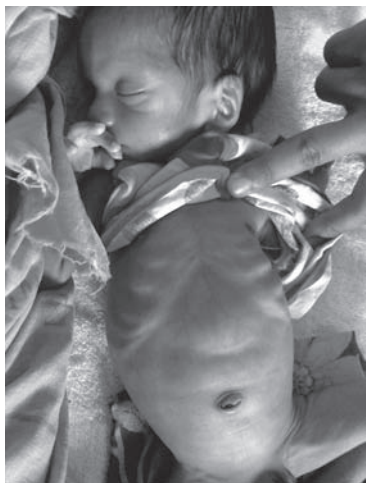**Table 2:** Arterial blood gas changes

At admission	Post-pericardiocentesis	
	D0	D1
pH: 7.202	pH: 7.445	pH: 7.475
pCO <sub>2</sub> : 41.7 mm Hg	pCO <sub>2</sub> : 23.7 mm Hg	pCO <sub>2</sub> : 23.8 mm Hg
pO <sub>2</sub> : 107 mm Hg	pO <sub>2</sub> : 125 mm Hg	pO <sub>2</sub> : 114 mm Hg
BE: -17.7 mmol/L	cHCO <sub>3</sub> <sup>-</sup> : 16.3 mm Hg	cHCO <sub>3</sub> <sup>-</sup> : 17.5 mm Hg
Na <sup>+</sup> : 117 mmol/L	BE: -7.7 mmol/L	BE: -6.7 mmol/L
K <sup>+</sup> : 4.3 mmol/L	Na <sup>+</sup> : 116 mmol/L	Na <sup>+</sup> : 115 mmol/L
	K <sup>+</sup> : 4 mmol/L	K <sup>+</sup> : 4.6 mmol/L

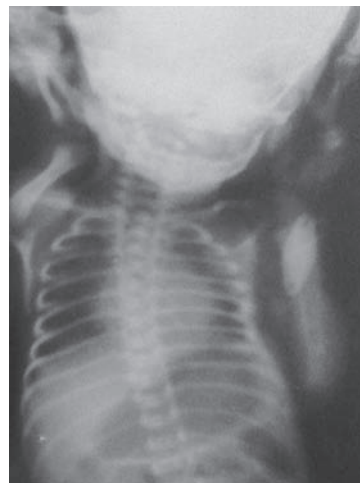23,000 leukocyte count, 90% lymphocyte preponderance, elevated sugar and protein, ADA: 140.5 IU/L, and elevated LDH as well (9,650 U/L). Elevated ADA >40 IU/L has an 87% specificity for TB and treatment was, hence, tailored to that.

Her condition improved with pericardial tap (Table 2), but electrolyte changes and slowly improving Glasgow Coma Scale meant she was in intensive care unit (ICU) under multidisciplinary team for few more days. The elevated LDH and ADA made us revisit the history and this time on probing, history of TB diagnosed 2 months back was revealed, which had initially been kept from us in view of social stigma. The negative AFB smears at present and the fact that she defaulted her treatment meant she was instituted extended category 2 ATT after coming out of the ICU and gradually she made a steady recovery.

**SCENARIO 2:** A 31-year-old lady had booked and presented in her third pregnancy at 34 weeks with chronic cough and shortness of breath for 1 month (Figs 3 and 4). Fortunately, in her case, a sputum AFB revealed 3+ bacilli and she was instituted on category 1 ATT soon. However, she went into preterm labor and delivered a male baby weighing 1,650 gm that was small for gestational age who needed SNCU admission, and in view of active TB in the



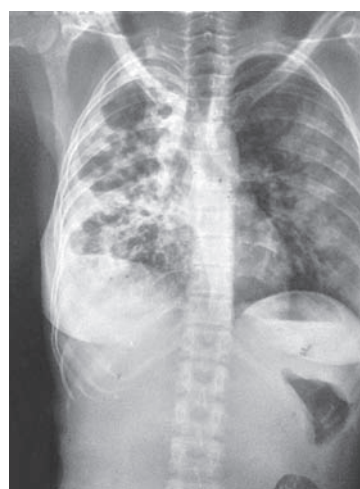**Fig. 3:** Neonate with congenital TB with subcostal retractions, dilated subcutaneous abdominal veins



**Fig. 4:** Same neonate with hepatosplenomegaly on X-ray



**Fig. 5:** Supraclavicular hollowing in the mother with few enlarged lymph nodes



**Fig. 6:** Chest X-ray

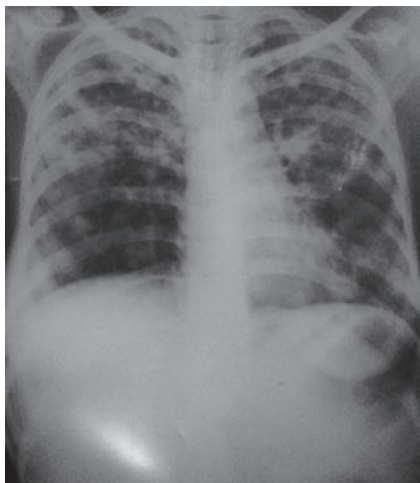
mother, the child was not commenced immediately on exclusive breastfeeding. Repeated episodes of secondary apnea in SNCU were followed by a gastric aspirate revealing AFB 1+ in smears. The placenta had been sent for histopathology and revealed noncaseating tuberculous granulomas. A diagnosis of congenital TB fulfilling Cantwell's criteria was made with hepatosplenomegaly present in both mother and baby (Figs 5 and 6).

A multidetector CT thorax of the mother performed postnatally was suggestive of diffuse air space consolidation of all segments of right lung with multiple cavities, pleural thickening, multiple centrilobular opacities in right lower lobe, as well as in left apicoposterior and lingular lobes with *tree-in-bud* appearance. Her corresponding X-ray picture is depicted in Figure 4. She was continued on ATT postnatally and turned sputum-negative after 3 months. Her infant was started on ATT and both underwent follow-up in chest OPD.

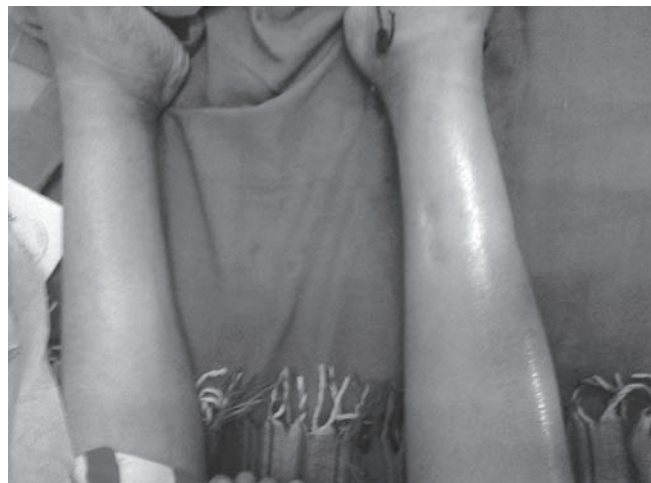SCENARIO 3: The outcome of this lady in her

first pregnancy with late booking and active primary pulmonary TB (Fig. 7) was rather disastrous. She was referred from a block primary health center, been started on ATT 7 days back after a diagnosis of pulmonary TB with 3+ AFB on smear. She was admitted at 32 weeks in advanced preterm labor and breathlessness. She was febrile and we could not give her corticosteroids for fetal lung maturity. A 1,300 gm grossly premature and growth-restricted baby was delivered, who succumbed in SNCU after 28 days of care.

The lady herself developed respiratory distress postnatally a week after delivery and while DVT was suspected clinically (Fig. 8) with calf tenderness, the presence of compressible femoral and popliteal vessels on USG meant that low molecular-weight heparin (LMWH) was administered late and at lower prophylactic doses than was needed. Recovery was not on expected lines, even with ATT and with antibiotics for superimposed lung infection, and things took a fatal turn for the worse



**Fig. 7:** Chest X-ray of lady with DVT



**Fig. 8:** Deep venous thrombosis

suddenly in third postnatal week with sudden onset chest pain, breathlessness, and desaturation. She could not be revived following this respiratory collapse. We obtained informed consent from her relatives for a postmortem. A saddle thrombus in the pulmonary vessels among findings of lung fibrosis and cavitation was a great learning point for us to be less conservative when instituting anticoagulation for treating medical disorders leading to immobility in the puerperium.

**SCENARIO 4:** An interesting scenario was seen with a lady  $G_2P_{1+0}$  who had arrived for the first time in her second pregnancy in emergency with history of convulsions at 24 weeks of gestation, a BP of 140/94 mm Hg, and cough. Suspecting eclamptic seizures and cough due to aspiration, she received prophylactic  $MgSO_4$  intramuscular and intravenous loading doses, but seizures refused to subside even with further intravenous magnesium sulfate and intravenous phenytoin. With decreasing consciousness and mentation, and papilledema on eye fundus examination, a CT brain was requested and this revealed a hypodense space-occupying lesion in frontal lobe. A Mantoux was also detected positive and subsequent smears revealed 3+ AFB. Her consciousness rapidly improved after institution of ATT and intravenous dexamethasone that helped in reducing the cerebral edema and she was discharged at 28 weeks after reassuring fetal status on umbilical artery Doppler. She was continued on ATT throughout pregnancy and even after delivery with 2- to 4-weekly LFTs. She delivered a 2,150 gm baby girl at 36 weeks by which time she was already sputum-negative and with no further episodes of seizures.

**SCENARIO 5:** Of the women who had better outcomes, there was a well-educated 26-year-old lady working as a staff nurse in a subdivision hospital, who had been diagnosed sputum-positive at 8 weeks of gestation, referred from the chest medicine outpatient. She came with unfounded concern of having to terminate

her pregnancy, which thankfully was allayed by careful counseling. We started her with ATT category 1 at 9 weeks of gestation, weighing and discussing with her the small risks of teratogenicity against the definite benefits. A 12 weeks USG revealed a normal nuchal translucency and a normal anomaly scan at 19 weeks helped reassure her. However, at around 28 weeks of gestation, she complained of itching in soles of feet, not unlike intrahepatic cholestasis, and an initial LFT revealed serum glutamic pyruvic transaminase of 104 IU/L and serum glutamic oxaloacetic transaminase of 171 IU/L. After seeking pulmonary medicine opinion, we instituted ursodeoxycholic acid treatment at 300 mg bd dosage and while itching subsided sooner after 1 to 2 weeks, her liver enzymes gradually stabilized to 44 and 62 IU/L in the next 4 weeks. She spontaneously went into labor at 37 weeks of gestation and delivered a healthy 3,050 gm male baby. She proceeded to complete her ATT. The cholestatic effect of antitubercular drugs like rifampicin in pregnancy, if any, as noted in her, was not seen in the other three patients, who presented early and delivered at-term, and this needs to be studied in a larger trial.

Yet another patient had conceived after primary infertility with tube having beaded appearance of tubes on hysterosalpingogram (HSG) suggestive of old TB endometritis. She was the only one among 10 patients with tubal infertility due to TB, in the period of study, to conceive, incidentally after the HSG. She had completed ATT prior to pregnancy and maternal and fetal outcomes were similar to normal gestations.

## DISCUSSION

Clinical features of TB have not been found to be any different in the pregnant and nonpregnant women. Clinical disease can only be suspected in presence of active disease, while half to two-thirds of pregnant women with



TB are asymptomatic, mostly due to latent infection.<sup>5,6</sup> Early disease and nonspecific constitutional symptoms like malaise and fatigue can mimic the physiological changes in pregnancy,<sup>7,8</sup> and this was a challenge that we faced for women who presented early in pregnancy, but had not been diagnosed already as TB. Both pulmonary and extrapulmonary TB can present with constitutional symptoms and, in our study, malaise and loss of appetite were the most common symptoms noted as compared with fever, night sweats, and weight loss, which were noted only in the three women presenting in advanced gestation with active TB and the lady with TB pericarditis.

Pregnancy neither has a beneficial nor detrimental effect on course of TB including sputum conversion rate, stabilization of disease, and relapse rates<sup>9,10</sup> as long as it is diagnosed and treated without delay. This is a trend we noticed among the women who presented early in pregnancy with recent onset of disease, who had a largely uneventful course and delivered healthy babies. As in other studies,<sup>11</sup> we noted that the anatomic extent of disease, the radiographic pattern, and the individual's susceptibility to the disease decided the course and prognosis of the disease in pregnancy rather than pregnancy itself.

Literature has been rather conflicting regarding the effect of TB on pregnancy. A rather old Norwegian study<sup>5</sup> suggested higher incidence of preeclampsia, postpartum hemorrhage, and difficult labor, but subsequent studies<sup>12</sup> have linked preeclampsia, preterm labor, and respiratory failure only in late diagnosed cases. This has been a feature noted in our study as well with preterm labor, fetal growth restriction, and maternal respiratory failure limited to women presenting late. Extrapulmonary TB may not have a direct effect on pregnancy outcomes, but is associated with morbidity in terms of recurrent hospital admissions, disability as in TB spine, and also fetal growth restriction, low Apgar scores particularly with TB spine, abdomen, and CNS.

Mantoux testing using purified protein derivative of 0.1 mL is safe in pregnancy and not affected by pregnancy as such.<sup>13</sup> However, increased false positives as in non-TB mycobacterium, previous Bacillus Calmette-Guerin (BCG), and false negatives as in very old infections/overwhelming TB disease may render this test redundant and, therefore, despite being widely available, we have not used Mantoux in our study. Chest X-ray involving <0.01 mGy is safe in pregnancy, and we have used it to determine extent of pulmonary involvement and active disease, particularly, in women presenting late. Sputum smears remain the gold standard and have been used most extensively even though it may be negative in paucibacillary cases and due to technical errors. Gastric/bronchial/tracheal lavage can be used for obtaining smears

and culture for AFB, as and when required; we used it to obtain samples from those with poor sputum production and to rule out congenital TB. Immunological tests like QuantiFERON TB Gold has less evidence for use in pregnancy even though specificity and sensitivity may be better than Mantoux. Additional imaging studies like CT thorax were used in the puerperium and MRI/CT spine, if such extrapulmonary manifestations were present.

Congenital TB is very rare though we did find it in one of the infants. Typically, these infants present in the second or third week postnatally with hepatosplenomegaly, fever, poor feeding, respiratory distress, and low weight gain. Cantwell's diagnostic criteria need one of the following diagnostic criteria: lesions in the first week of life, a primary hepatic complex/caseating granuloma, documented TB infection in placenta/endometrium, and exclusion of transmission postnatally by potential contacts.

Pregnant women with TB should be managed by a multidisciplinary team comprising obstetrician, microbiologist, chest physician, and, where possible, a specialist TB nurse. The ATT is initiated by the chest physician, while our role as obstetricians will be to ensure proper compliance along with fetomaternal monitoring. Inpatient admission is mandated in very sick smear-positive women, highly infectious, and MDR-TB cases. The chemotherapy consists of an initial IP wherein rifampicin, isoniazid, and ethambutol remain the first choice, while addition of pyrazinamide is desirable at least for the initial 2 months. Streptomycin is contraindicated and a two/three drug continuation phase regime helps prevent drug resistance, eliminate residual bacilli, and prevent failures and relapses. Infection control in late pregnancy and puerperium can be particularly challenging in sputum-positive patients, and an initial treatment with isoniazid and rifampicin is helpful in making them noninfectious by 2 weeks.

Tuberculosis diagnosed postnatally, particularly with mother testing sputum-positive within 2 weeks after delivery can increase chances of neonatal transmission. Infant with a mother, who has received less than 2 weeks of treatment and is sputum-positive should receive isoniazid at 5 mg/kg along with pyridoxine 5 to 14 mg/kg, and infant should have a tuberculin test at 6 to 12 weeks.<sup>14</sup> If this is negative, BCG vaccine can be given and treatment stopped. If positive, treatment needs to be extended to 6 months. The BCG is not recommended to infants of mothers who are HIV+, unless the infants have been found to be HIV-negative. For mothers who are on ATT, breastfeeding remains a safe and feasible option.

Any time of immobility in pregnancy or postnatally due to medical disorders, such as advanced TB or others need thromboprophylaxis in accordance to the latest Royal College of Obstetricians and Gynaecologists

guidelines.<sup>15</sup> A venous thromboembolism risk assessment needs to be done and LMWH instituted according to risk levels and body weight. Treatment doses of DVT need to be more frequent (twice daily) and for longer duration postnatally, sometimes up to 6 weeks, compared with prophylactic doses. General measures like adequate hydration and compression stockings need to be added.

## CONCLUSION

Our study was the first of its kind to observe effects of TB on pregnancy in a resource-poor setting of rural Eastern India. Despite obvious limitation of a small sample, more such studies need to be encouraged, as TB is very much a curable and preventable disease, and patient's and health care personnel's education at grassroot levels can greatly limit the morbidity in pregnancy as well as help in general well-being. Multidisciplinary involvement of a cardiologist, neurologist, along with the core team, can help in proper diagnosis and treatment of extrapulmonary manifestations including longer duration of drug treatment and other supportive care. Deep venous thrombosis when clinically suspected should not be ruled out after a single negative compression USG; treatment doses of anticoagulation need to be commenced and compression USG needs to be serially repeated until DVT can be conclusively ruled out.

## REFERENCES

1. Global Tuberculosis Control 2015. Geneva: WHO; 2015. Available from: [www.who.int/tb/publications/global\\_report/](http://www.who.int/tb/publications/global_report/)
2. TB India 2015 Revised National TB Control Programme Annual Status Report, New Delhi; 2015. Available from: [www.tbindia.nic.in/](http://www.tbindia.nic.in/)
3. WHO: Tuberculosis in women Nov 2015 Fact Sheet. Available from: [www.who.int/tb](http://www.who.int/tb)
4. Roy TK, Sarker G, Gupta A, Ghosh S, Sarbapalli D, Pal R. Bridging gaps in revised national tuberculosis control program at Bankura District, West Bengal State, India. *Am J Public Health Res* 2015;3(5A):130-134.
5. Bjerkedal T, Bahna SL, Lehmann EH. Course and outcome of pregnancy in women with pulmonary tuberculosis. *Scand J Resp Dis* 1975;56(5):245-250.
6. Wilson EA, Thelin TJ, Dilts PV. Tuberculosis complicated by pregnancy. *Am J Obstet Gynecol* 1973 Feb;115(4): 526-259.
7. Llewelyn M, Cropley I, Wilkinson RJ, Davidson RN. Tuberculosis diagnosed during pregnancy: a prospective study from London. *Thorax* 2000 Feb;55(2):129-32. doi:10.1136/thorax.55.2.129
8. Hamadeh MA, Glassroth J. Tuberculosis and pregnancy. *Chest* 1992 Apr;101(4):1114-1120. doi:10.1378/chest.101.4.1114
9. Tripathy SN, Tripathy SN. Tuberculosis and pregnancy. *Int J Gynaecol Obstet* 2003 Mar;80(3):247-253. doi:10.1016/S0020-7292(02)00393-4
10. Mahendru A, Gajjar K, Eddy J. Diagnosis and management of tuberculosis in pregnancy. *Obstet Gynaecol* 2010;12(3): 163-171.
11. Starke JR. Tuberculosis. An old disease but a new threat to the mother, fetus, and neonate. *Clin Perinatol* 1997 Mar;24(1): 107-127.
12. Jana N, Vasishtha K, Jindal SK, Khunnu B, Ghosh K. Perinatal outcome in pregnancies complicated by pulmonary tuberculosis. *Int J Gynecol Obstet* 1994 Feb;44(2):119-124. doi:10.1016/0020-7292(94)90064-7
13. Centres for Disease Control and Prevention, Division of Tuberculosis Elimination, Tuberculin Skin Testing. Fact sheets; May 2007.
14. Health Protection Agency. Pregnancy and Tuberculosis, NHS Guidance for Clinicians. London: HPA; March 2006.
15. Reducing the risk of venous thromboembolism during pregnancy and the puerperium, RCOG Green-top Guideline No. 37a, April 2015.