

## CASE REPORT

# Selective Uterine Artery Embolization: An Effective Treatment Option for Postpartum Hemorrhage due to Pseudoaneurysm of Uterine Artery

<sup>1</sup>Radhika Gollapudi, <sup>2</sup>S Rammurthy

## ABSTRACT

**Aim:** To demonstrate the efficacy of uterine artery embolization in the management of postpartum hemorrhage (PPH) due to pseudoaneurysm of the uterine artery.

**Background:** Postpartum hemorrhage is a leading cause of maternal mortality in India. Secondary PPH is a rare cause but potentially life threatening. Common causes of secondary PPH are retained products of conception, subinvolution of uterus, and endometritis. Pseudoaneurysm is an uncommon cause of secondary PPH following operative delivery. Color Doppler ultrasound is a useful diagnostic tool and angiography is necessary to localize and treat by embolization.

**Case report:** We report two cases of secondary PPH due to pseudoaneurysm of uterine artery, which were managed by selective embolization of uterine artery.

**Conclusion:** Angiographic embolization of uterine artery is a safe and reliable technique for management of secondary PPH due to pseudoaneurysm. If diagnosed early, the need for hysterectomy is prevented.

**Clinical significance:** Uterine artery embolization has emerged as a simple, effective, and fertility-sparing treatment for PPH.

**Keywords:** Pseudoaneurysm of the uterine artery, Secondary postpartum hemorrhage, Uterine artery embolization.

**How to cite this article:** Gollapudi R, Rammurthy S. Selective Uterine Artery Embolization: An Effective Treatment Option for Postpartum Hemorrhage due to Pseudoaneurysm of Uterine Artery. J South Asian Feder Obst Gynae 2017;9(3):283-286.

**Source of support:** Nil

**Conflict of interest:** None

**Date of received:** 2 May 2017

**Date of acceptance:** 25 June 2017

**Date of publication:** August 2017

## BACKGROUND

Obstetric hemorrhage is a major cause of concern due to high maternal morbidity and mortality, more so in

developing countries. Postpartum hemorrhage (PPH) has received little attention and hence, remains the most severe and underestimated complication of pregnancy. It occurs in less than 5% of all deliveries but accounts for 15% of all maternal deaths.<sup>1</sup> Among the two types of PPH, secondary PPH, though rare, when severe can be fatal. Secondary PPH is defined as excessive bleeding from the genital tract after the initial 24 hours following delivery up to 6 to 12 weeks of puerperium.<sup>2</sup>

Uterine subinvolution, endometritis, and retained products of conception have been identified as the most common causes of secondary PPH.<sup>3</sup> Pseudoaneurysms and arteriovenous malformations are rare causes of secondary PPH.<sup>4</sup> The newer and latest techniques of investigation like ultrasound, color Doppler, and angiography have made diagnosis of pseudoaneurysms easy and accurate.

Primary treatment modalities, such as resuscitation, uterotonics, and appropriate antibiotics, are administered to control secondary PPH. When these are ineffective, dilatation and curettage, pelvic arterial ligation, or hysterectomy may be required to control intractable bleeding per vaginuum.

Uterine artery embolization is a minimally invasive, quick, safe, and effective procedure for management of secondary PPH due to pseudoaneurysms. This not only retains the fertility of the woman but also avoids a major surgical procedure, such as hysterectomy.

We report two cases of secondary PPH due to pseudoaneurysm of uterine artery post a lower segment cesarean section (LSCS) which were successfully treated with selective uterine artery embolization.

## CASE REPORTS

### Case 1

A 29-year-old para 1, abortion 2 was referred to our institute with secondary PPH. She had undergone encirclage for short cervix at 14 weeks of gestation and subsequent antenatal period was uneventful. Emergency LSCS was performed at term for cephalopelvic disproportion and patient delivered a male baby of 2.75 kg. On the 7th postoperative day, she developed excessive bleeding per vaginuum for which she was evaluated.

<sup>1</sup>Assistant Professor, <sup>2</sup>Professor and Head

<sup>1</sup>Department of Obstetrics and Gynecology, Nizam's Institute of Medical Sciences, Hyderabad, Telangana, India

<sup>2</sup>Department of Radiology, Nizam's Institute of Medical Sciences Hyderabad, Telangana, India

**Corresponding Author:** Radhika Gollapudi, Assistant Professor Department of Obstetrics and Gynecology, Nizam's Institute of Medical Sciences, Hyderabad, Telangana, India, Phone: +919848806321, e-mail: dr.radhika.gollapudi@gmail.com

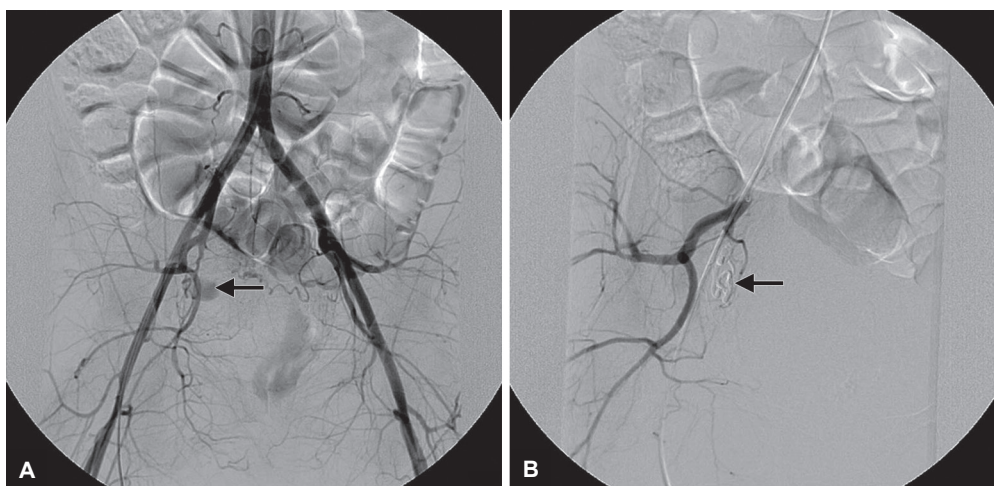
Investigations revealed a hemoglobin of 7.6 gm%, total leukocyte count and platelets were within normal limits. Ultrasound showed no products of conception in the uterus. She was transfused 2 units of packed red cells and treated with oxytocics and antibiotics. Her bleeding subsided and she was discharged. On 15th postoperative day, patient presented again with excess bleeding per vaginuum and was readmitted to the hospital and investigated further. Her hemoglobin was 4.6 gm%, packed cell volume was 13%, and platelets were adequate. Liver function tests were within normal limits. Quantitative human chorionic gonadotropin was less than the normal limits. Ultrasound showed hyperechoic shadows in the endometrial cavity. She was transfused 2 units of blood after which patient developed hematuria and hence, was shifted to our institute for further management. On admission, patient was conscious, coherent, and afebrile with stable vitals. Per abdomen examination revealed a well-healed Pfannenstiel scar, uterine size was 16 weeks with no tenderness. There was hematuria, cervical and vaginal tears were ruled out. Her routine blood investigations revealed hemoglobin of 4.8 gm%, packed cell volume of 13%, total leukocyte count was 8,500/cumm, and platelets were adequate. Serum creatinine was 6 mg/dL, and blood urea was 99 mg/dL. Coagulation profile was normal. Ultrasound and color Doppler were done which showed endometrial collection and signs of pseudoaneurysm of uterine artery. Patient received three sessions of hemodialysis and subsequently her serum creatinine decreased. Interventional radiologist was consulted and patient was taken up for angiography, after localization of the pseudoaneurysm of the right uterine artery (Fig. 1A) selective arterial embolization was done using glue [N-butyl-2-cyanoacrylate (NBCA)/Histoacryl/B Braun] (Fig. 1B).

Postembolization arteriography showed obliteration of flow in the pseudoaneurysm. Blood transfusion was given as required and no further hemodialysis was needed. At discharge, hemoglobin was 8.3 gm%, packed cell volume was 26%, blood urea was 48 mg/dL, and serum creatinine was 1.2 mg/dL. With no further complications, patient's general condition improved and was discharged on hematinics. Follow-up ultrasound and color Doppler showed a well-retracted uterus with no signs of pseudoaneurysm.

## Case 2

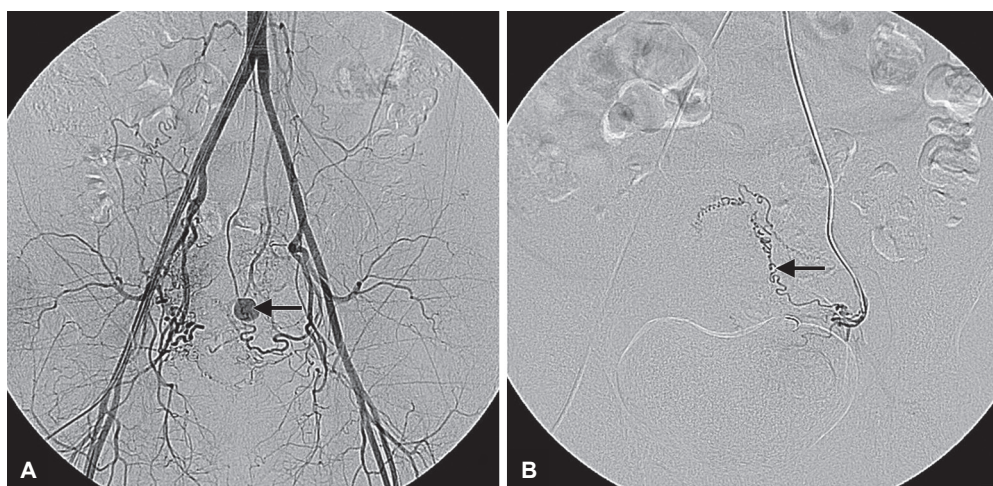
A 38-year-old para 2, live 2 was referred to our institute with secondary PPH following a term LSCS. Patient had an uneventful antenatal and intraoperative period. She developed recurrent episodes of excessive and prolonged bleeding per vaginuum for which she was treated conservatively at a local hospital. On 22nd postnatal day patient was admitted with same complaints. Investigations revealed hemoglobin 8 gm%, packed cell volume 25%, platelets 1.2 lakhs/cumm. Ultrasound showed collection in the endometrial cavity. Dilatation and curettage was done and patient was put on oxytocics and antibiotics. She was discharged as her condition improved. On 26th postnatal day, patient presented again with excessive bleeding and hence, was referred to our institute for further management.

On admission, patient was pale, afebrile with stable vitals. Per abdominal examination showed a well-healed cesarean scar and per vaginal examination revealed no abnormalities. Ultrasound and color Doppler were done which showed signs of a left uterine artery pseudoaneurysm. As the patient was hemodynamically stable, angiography was done. Site of pseudoaneurysm localized (Fig. 2A) and selective uterine artery embolization



**Figs 1A and B:** (A) Aortogram shows pseudoaneurysm from right uterine artery (arrow). (B) Selective right internal iliac arteriogram shows obliteration of flow in the pseudoaneurysm following glue (NBCA) embolization of the feeding artery (arrow)





**Figs 2A and B:** (A) Aortogram shows pseudoaneurysm (arrow) from the left uterine artery; and (B) Selective left uterine artery embolization shows obliteration of flow in pseudoaneurysm following coil embolization of the feeding vessel

was performed using pushable coil (Hilal/Cook/0.018") (Fig. 2B). Bleeding per vaginuum gradually decreased and stopped. Follow-up color Doppler study showed no evidence of blood flow to the embolized site.

## DISCUSSION

Pseudoaneurysm is a known complication of vascular injury secondary to surgical intervention. It is defined as extraluminal collection of blood with turbulence communicating with flowing arterial blood due to defect in the arterial wall. Pseudoaneurysm is a rare cause of secondary PPH. Color Doppler and real-time ultrasound provide a simple, reliable, and inexpensive modality of diagnosis. Pseudoaneurysm should be suspected on ultrasound if anechoic structures are found. The "To and Fro" Doppler sign in the neck of pseudoaneurysm and the "Yin Yang" sign in the body are diagnostic.<sup>5,6</sup> Angiographic study effectively localizes the site of pseudoaneurysm.

Transcatheter arterial embolization has been a recognized method of controlling hemorrhage since the 1960s, and has been used to control pelvic bleeding secondary to malignancy, trauma, and postradiation.<sup>7</sup> Several agents for embolization like gelatin sponge pledgets, polyvinyl alcohol particles, and steel coils are currently in use. Brown et al<sup>8</sup> reported the first case of selective arterial embolization to successfully treat extrauterine pelvic hematoma to control bleeding. Nanjundan et al<sup>5</sup> reported a case of secondary PPH on 19th day post-LSCS, which was treated by embolization of the uterine artery. Our patients presented with PPH during 4 to 6 weeks after LSCS. They were initially managed conservatively and various treatment options were considered. Since both of our patients were desirous of retaining fertility, selective uterine artery embolization was preferred to surgical intervention.

The other advantages of uterine artery embolization are exact identification of bleeding site, repeat embolization if necessary, and avoidance of general anesthesia.<sup>6</sup> The efficacy and safety of uterine artery embolization was evaluated by Pelage et al<sup>9</sup> in a study of 14 patients with secondary PPH; out of the 14 patients 2 were treated for secondary PPH due to pseudoaneurysm by embolization. The success rate following embolization is reported to be 97%.<sup>10</sup> Badaway et al<sup>11</sup> reported a success rate of 94.9% in a series of 138 patients of PPH managed by arterial embolization. Both of our cases of secondary PPH due to pseudoaneurysm were managed successfully by selective uterine artery embolization. In our cases, no complications were observed postarterial embolization. The most common complication reported is low-grade fever, rarer complications include groin hematoma, pelvic infection, and bladder necrosis.

## CONCLUSION

With advent of newer modalities of diagnosis and treatment, hysterectomy should be a last resort of treatment for vascular injuries subsequent to surgical intervention procedures like LSCS. Color Doppler and angiography are highly effective means of diagnosis and accurate localization of pseudoaneurysm.

## CLINICAL SIGNIFICANCE

Selective arterial embolization being a minimally invasive procedure and having the advantage of sparing fertility should be offered as a primary treatment modality especially in young patients. Rapid and effective diagnosis and subsequent intervention with embolization can lead to a significant decline in morbidity and mortality associated with PPH.

## REFERENCES

1. Wald DA. Postpartum hemorrhage resulting from uterine artery pseudoaneurysm. *J Emerg Med* 2003 Jul;25(1):57-60.
2. ACOG Practice Bulletin. Clinical management guidelines for obstetrician-gynecologists: post-partum hemorrhage. *Obstet Gynecol* 2006 Oct;108(4):1039.
3. Khong TY, Khong TK. Delayed postpartum hemorrhage: a morphologic study of causes and their relation to other pregnancy disorders. *Obstet Gynecol* 1993 Jul;82(1):17-22.
4. Cooper BC, Hocking-Brown M, Sorosky JJ, Hansen WF. Pseudoaneurysm of the uterine artery requiring bilateral uterine artery embolization. *J Perinatol* 2004 Sep;24(9):560-562.
5. Nanjundan P, Rohilla M, Raveendran A, Jain V, Khandelwal N. Pseudoaneurysm of the uterine artery: a rare cause of secondary post partum hemorrhage managed with uterine artery embolization. *J Clin Imaging Sci* 2011 Feb;1:14.
6. Chitra TV, Panicker S. Pseudoaneurysm of the uterine artery: a rare cause of secondary postpartum hemorrhage. *J Obstet Gynaecol India* 2011 Nov-Dec;61(6):641-644.
7. Wee L, Barron J, Toye R. Management of severe postpartum haemorrhage by uterine artery embolization. *Br J Anaesth* 2004 Oct;93(4):591-594.
8. Brown BJ, Heaston DK, Poulson AM, Gabert HA, Mineau DE, Miller Jr FJ. Uncontrollable Postpartum Bleeding: a new approach to hemostasis through angiographic arterial embolization. *Obstet Gynecol* 1979;54:361-365.
9. Pelage JP, Soyer P, Repiquet D, Herbreteau D, Le Dref O, Houdart E, Jacob D, Kardache M, Schurando P, Truc JB, et al. Secondary postpartum hemorrhage. Treatment with selective arterial embolization. *Radiology* 1999 Aug;212(2):385-389.
10. Vedantham S, Goodwin SC, McLucas B, Mohr G. Uterine artery embolization: an underused method of controlling pelvic hemorrhage. *Am J Obstet Gynecol* 1997 Apr;176(4):938-948.
11. Badaway SZA, Etman A, Singh M, Murphy K, Mayelli T, Philadelphia M. Uterine artery embolization: the role in obstetrics and gynecology. *J Clin Imaging* 2001 Jul-Aug;25(4):288-295.