

## CASE REPORT

# Vaginoplasty with Uterovaginal Anastomosis for partial Vaginal and Complete Cervical Agenesis: A Rare Müllerian Anomaly

<sup>1</sup>Vineet V Mishra, <sup>2</sup>Rajani Nawal, <sup>3</sup>Rohina Aggarwal, <sup>4</sup>Sakshi Nanda, <sup>5</sup>Pradeep Bandwal, <sup>6</sup>Khushali Gandhi

## ABSTRACT

Congenital absence of cervix is a rare condition that occurs in 1 in 80,000 to 100,000 births. Here, we report a case of a 20-year-old, married woman who presented to the gynecology outpatient department with primary amenorrhea and complaints of cyclical left-sided lower abdominal pain and difficult coitus for 2 years. Magnetic resonance imaging report suggested unicornuate uterus with hematometra and cervical agenesis. On laparotomy, unicornuate globular uterine horn with absent cervix was present on the left side and separate solid rudimentary horn was found on right lateral pelvic wall. Left adnexa was normal, whereas right ovary was enlarged with minimal hydrosalpinx. Vaginoplasty with uterovaginal anastomosis was performed after draining the hematometra and successful restoration of cyclical menses was achieved on follow-up.

**Keywords:** Cervical agenesis, Hematometra, Unicornuate uterus.

**How to cite this article:** Mishra VV, Nawal R, Aggarwal R, Nanda S, Bandwal P, Gandhi K. Vaginoplasty with Uterovaginal Anastomosis for partial Vaginal and Complete Cervical Agenesis: A Rare Müllerian Anomaly. *J South Asian Feder Obst Gynae* 2017;9(3):274-276.

**Source of support:** Nil

**Conflict of interest:** None

**Date of received:** 5 May 2017

**Date of acceptance:** 2 July 2017

**Date of publication:** August 2017

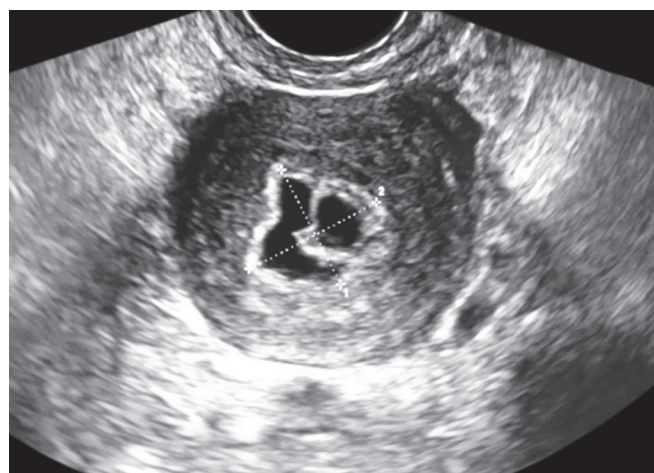
## INTRODUCTION

Müllerian anomalies are not uncommon conditions, with mean prevalence in the general population of about 4%.<sup>1</sup> Congenital absence of the cervix is a rare condition, which occurs in 1 in 80,000 to 100,000 births.<sup>2</sup> It is known to be

associated with both partial and complete vaginal aplasia. According to the American Fertility Society, cervical agenesis is classified as a class IIb uterovaginal anomaly. Clinical presentation is usually primary amenorrhea and cyclical lower abdominal pain, as seen in our patient.

## CASE REPORT

A 20-year-old woman married for 2 years was referred to our department with primary amenorrhea and complaints of monthly left lower abdominal pain and difficulty in coitus for 2 years. On examination, she was averagely built and nourished with normal secondary sexual characteristics. Abdomen was soft with mild tenderness in left lower abdomen. On local examination, normal external genitalia and well-developed pubic hair were present with 1 cm deep blind pouch of vagina with two pinpoint dimples in the center of pouch. As per rectal examination, about 6 × 5 cm tense, globular, freely mobile mass was palpated on left side. Ultrasound examination showed unicornuate left uterine horn with hematometra (Fig. 1), and magnetic resonance imaging (MRI) findings suggested unicornuate left-sided small uterus with hematometra, hypoplastic lower uterine segment, cervical aplasia, normal size b/l ovaries, normal left fallopian tube, and right-sided mild hydrosalpinx. All routine investigations including electrocardiogram and intravenous pyelogram were normal. Vaginoplasty

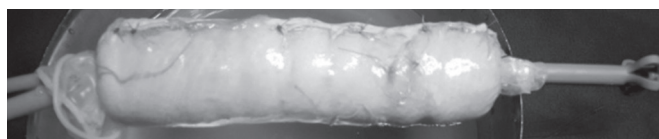


**Fig. 1:** Ultrasonography showing left uterine horn with hematometra

<sup>1</sup>Professor and Head, <sup>2,4,5</sup>Clinical Fellow, <sup>3</sup>Associate Professor  
<sup>6</sup>Junior Lecturer

<sup>1-6</sup>Department of Obstetrics and Gynecology, Smt. G.R. Doshi and Smt. K.M. Mehta Institute of Kidney Diseases and Research Centre, Ahmedabad, Gujarat, India

**Corresponding Author:** Vineet V Mishra, Professor and Head Department of Obstetrics and Gynecology, Smt. G.R. Doshi and Smt. K.M. Mehta Institute of Kidney Diseases and Research Centre, Ahmedabad, Gujarat, India, Phone: +917922687038 e-mail: vineet.mishra.ikdrc@gmail.com



**Fig. 2:** Split thickness graft-covered vaginal mold prepared over two Malecot's catheters

with uterovaginal anastomosis was planned as patient and her husband wanted to retain her uterus. Success rate, complications, and possibility of hysterectomy were explained. Proper counseling was done to reduce psychological stress and their essential cooperative role in the positive outcome of the procedure was informed.

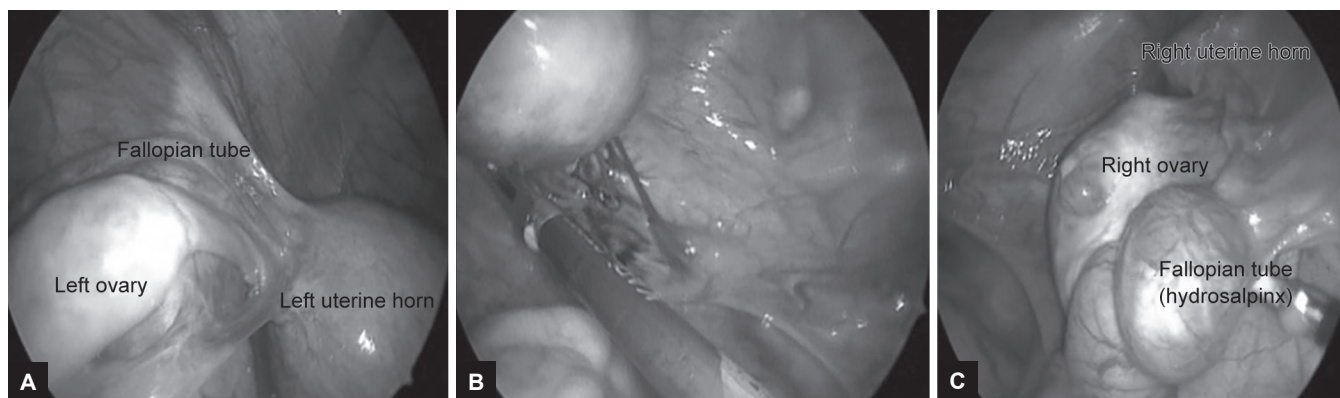
Vaginoplasty was planned by McIndoe technique in coordination with plastic surgeon to get split-thickness graft from thigh under general anesthesia. Preprepared vaginal mold was covered with skin graft (Fig. 2).

Dissection proceeded by digital manipulation, initially from vaginal side on either side of median raphe to reach the top of blind pouch, followed by laparotomy. During laparotomy, a globular uterine horn ( $6 \times 5$  cm) was seen on left side with elongated ovary and thin fallopian tube in communication with that horn. Round ligament was normal. Small knob-like noncommunicating rudimentary uterine horn ( $1 \times 1$  cm) was present on right lateral pelvic wall with small fallopian tube attached and enlarged ovary (Figs 3A to C). No communication was seen between left uterine horn and distal pouch of vagina. Two uterine horns were far apart. A small midline anterior wall stab incision given over the left uterine horn to drain hematometra and endocavity was examined through 2.9 mm hysteroscope, which showed normal endometrium with absence of cervix. A probe was inserted into uterine cavity after hysteroscopy and a small incision given at the hypoplastic lower uterine segment of the left uterine horn. Bladder was reflected down to get space for communication between neovagina and lower uterine segment. A Foley's catheter of 14F was passed from abdominal side to vaginal side

through uterine midline incision, followed through incisions given at lower hypoplastic uterine segment and top of created neovaginal space sequentially, where it was anchored after catheter balloon inflated with 10 mL normal saline. Before placing the mold inside, tips of Malecot's catheter (on the top of mold) and of Foley's catheter were tied by thread followed by deflation of Foley's balloon. The mold prepared for vaginoplasty was placed gently in the above-created space for neovagina under continuous negative pressure inside the mold through preplaced second red rubber catheter inside. Then, Foley's was pulled upward abdominally till incisions near fundus and tips of Foley's and Malecot's were untied, Foley's removed, and Malecot's catheter left inside uterine cavity along with the mold placed in neovaginal space to allow drainage of blood and to maintain patency of newly created tract. The lower uterine and upper neovaginal margins were sutured using polyglactin 910 no. 1-0 suture. Upper uterine small incision was apposed. Abdomen was closed back in layers. Few labial approximation stitches were applied to support mold. Patient stood the procedure well.

On day 11, mold was removed along with Malecot's catheter under short general anaesthesia. Graft was taken up well. Vagina washed with normal saline. On hysteroscopy, left uterine horn cavity and left tubal ostia were found normal. A new Malecot's catheter was fitted over 2.9 mm hysteroscope and placed inside uterine cavity under guidance and long end trimmed of at the level of cervix. It was left *in situ* for 1 month to prevent closure of the new tract. A new vaginal mold was placed inside neovagina supported with T-bandage. Oral contraceptive pills were given to the patient and taught for daily removal and reinsertion of the form and how to do a low-pressure douche of clear warm water for 6 weeks.

In follow-up, hysteroscopic examination done after 6 weeks showed normal endometrium and left tubal ostia. Neovagina was well. She started menses 2 months after the procedure and now has regularly for 2 months.



**Figs 3A to C:** Intraoperative findings suggestive of unicornuate uterine horn with absent cervix was present on the left side and separate solid rudimentary horn was found on right lateral pelvic wall

## DISCUSSION

Uterine cervix aplasia is a rare anomaly which can be associated with vaginal aplasia in 50% of cases.<sup>3</sup> Typically, patients with Müllerian agenesis present in adolescence with primary amenorrhea. To manage vaginal agenesis effectively in young women, correct diagnosis of the underlying condition is important. Differential diagnosis of vaginal agenesis includes androgen insensitivity, low-lying transverse septum, and imperforate hymen. Besides history, clinical examination, ultrasonography (transrectal, three-dimensional), MRI currently appears to be the most reliable morphological examination for the diagnosis of uterovaginal malformations with a surgical correlation >80%.<sup>4</sup> Laparoscopic exploration has the ability to assess the type of uterine malformation, and reveals other complications of the upper genital tract that may require appropriate surgery. Evaluation for associated renal (e.g., renal agenesis, pelvic kidney, duplex ureter) and skeletal anomalies is also essential.<sup>5</sup> Müllerian abnormalities causing obstruction of menstrual blood due to cervical or vaginal atresia are rare examples of malformation of the female genitalia. More recently, however, some attempts at preserving the uterus of these patients have been made in order to preserve their menstrual and reproductive capacity.<sup>6</sup> This was achieved by creating a "fistula" between the uterus and the vagina or between the uterus and a surgically formed neovagina, permitting normal flow between the endometrial cavity and the outer environment. These conservative techniques lead to relief of pain due to blood accumulation, and provide the psychological benefit by menstruation and the possibility of maternity. Previously, the recommended treatment for cervical agenesis was hysterectomy because complications of recanalizing the cervix were common and the possibility of a viable pregnancy was unlikely.<sup>7</sup>

Recent advances in reproductive technology and laparoscopic surgical techniques make conservative surgery a possibility and perhaps can be considered as the first-line treatment option.<sup>8</sup>

## CONCLUSION

Conservative procedures can be worthwhile for few carefully selected cases of cervical agenesis to allow a uterovaginal anastomosis in a highly specialized unit with the required expertise.

## REFERENCES

1. Grimbizis GF, Camus M, Tarlatzis BC, Bontis JN, Devroey P. Clinical implications of uterine malformations and hysteroscopic treatment results. *Hum Reprod Update* 2001 Mar-Apr;7(2):161-174.
2. Shah TN, Venkatesh S, Saxena RK, Pawar S. Uterovaginal anastomosis for complete cervical agenesis and partial vaginal agenesis: a case report. *Eur J Obstet Gynaecol Reprod Biol* 2014 Mar;174(1):154-155.
3. Barach B, Falces E, Benzian SR. Magnetic resonance imaging for diagnosis and preoperative planning in agenesis of the distal vagina. *Ann Plast Surg* 1987 Aug;19(2):192-194.
4. Deffarges JV, Haddad B, Musset R, Paniel BJ. Uterovaginal anastomosis in women with uterine cervix atresia: long term follow up and reproductive performance. A study of 18 cases. *Hum Reprod* 2001 Aug;16(8):1722-1725.
5. Fujimoto VY, Miller JH, Klein NA, Soules MR. Congenital cervical atresia: report of seven cases and review of the literature. *Am J Obstet Gynaecol* 1997 Dec;177(6):1419-1425.
6. Rock JA, Schlaff WD, Zacur HA, Jones HW Jr. The clinical management of congenital absence of the uterine cervix. *Int J Gynaecol Obstet* 1984 Jun;22(3):231-235.
7. Grimbizis GF, Tsalikis T, Milkos T, Papadopoulos N, Tarlatzis BC, Bontis JN. Successful end-to-end cervicocervical anastomosis in a patient with congenital cervical fragmentation: case report. *Hum Reprod* 2004 May;19(5):1204-1210.
8. Buttram VC Jr. Müllerian anomalies and their management. *Fertil Steril* 1983 Aug;40(2):159-163.