

## CASE REPORT

# A Rare Case of Ovarian Fibroma in a Teenage Girl

Vinita Singh

## ABSTRACT

**Introduction:** The ovarian fibroma is a rare benign tumor that accounts for 4% of all ovarian tumors, which grow from the connective tissue of the ovarian cortex. Among the sex cord-stromal tumors, fibromas are the most commonly encountered subtype, accounting for almost two-third of neoplasms in this group. The mean age of presentation is 48 years.

**Aims and objectives:** We present an unusual case of fibroma of the ovary presenting at 19 years of age with ascites. Diagnosis in our case was also difficult despite all tumor marker tests and clinical imaging being done, and finally it was confirmed by histopathology report.

**Discussion:** Fibromas and thecomas belong to a spectrum of benign ovarian tumors that are derived from ovarian stroma. Fibromas are the most common sex cord tumors and account for approximately 3 to 4% of all ovarian neoplasms. Ovarian fibromas are benign tumors of the ovary, difficult to diagnose preoperatively and can clinically and biochemically mimic ovarian cysts, tubo-ovarian mass, uterine myoma, or ovarian malignancy.

**Conclusion:** Fibroma must be distinguished from several nonneoplastic ovarian processes, specifically massive edema, fibromatosis, and stromal hyperplasia. Imaging is helpful to diagnose, but histopathology can only confirm the diagnosis.

**Keywords:** Benign ovarian tumor, Fibroma, Histopathology, Teenage girl.

**How to cite this article:** Singh V. A Rare Case of Ovarian Fibroma in a Teenage Girl. *J South Asian Feder Obst Gynae* 2017;9(2):125-127.

**Source of support:** Nil

**Conflict of interest:** None

**Date of received:** 22 November 2016

**Date of acceptance:** 22 January 2017

**Date of publication:** March 2017

## INTRODUCTION

Fibroma, thecomas, and fibrothecomas are rare benign tumors, which grow from the connective tissue of the

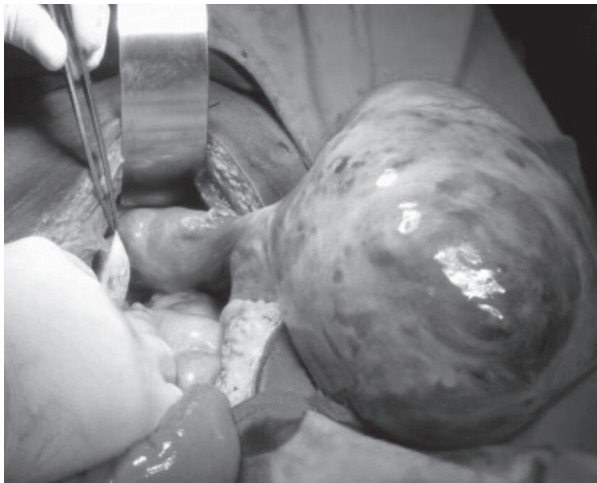
ovarian cortex. The mean age of occurrence is 45 to 55 years.<sup>1,2</sup> They are classified under sex cord-stromal tumors, which also include tumors composed of granulosa cells, theca cells, Sertoli cells, Leydig cells, and fibroblasts of stromal origin, singly or in various combinations.<sup>3</sup> Ovarian fibroma is a most common benign solid tumor that belongs to sex cord-stromal cell tumors of the ovary and comprises spindle-shaped fibroblastic cells and abundant collagen.<sup>5</sup> It accounts for 4% of all ovarian tumors.<sup>6</sup> Fewer than 10% of the cases are encountered under the age of 30 years. It may be functioning or nonfunctioning with endocrinal abnormalities. Affected women are asymptomatic or complain only of a palpable and progressive swelling mass in the inferior abdomen.<sup>7</sup> They can be unilateral in 90% of cases, and may vary in size from 3 to 15 cm.<sup>8</sup> In this case, the age of presentation of ovarian fibroma is less than that reported in literature and, hence, diagnosis was not confirmed until we got the histopathology report.

A 19-year-old unmarried nulliparous girl presented to us with painful abdomen on and off. She gave no history of menstrual irregularity, vaginal discharge, or any other significant symptoms. On general clinical examination, on per abdominal examination, mass of approximately 16 weeks size of pregnant uterus was palpated in hypogastric area arising from pelvis. Mass was firm-to-hard, smooth with well-defined margin and restricted mobility. Findings were confirmed on per vaginal examination with uterus palpable separately from the mass in the right fornix. Left ovary was also palpable bulky of approximately 3 × 2 cm. Ultrasound showed large solid hypoechoic mass arising from right ovary of 7.6 × 4.8 cm, and left ovary was 3.8 × 2.9 cm. Contrast-enhanced computed tomography (CECT) abdomen showed enhancing mass lesion arising from right ovary of size 9 × 6 × 5 cm with neurotic and fibrotic component. Tumor markers: Cancer antigen (CA) 125 = 10.7; alfa fetoprotein = 0.33; lactate dehydrogenase = 220 units. Montoux was negative. The girl was planned for exploratory laparotomy in view of ovarian tumor. On laparotomy, straw-colored ascitic fluid of about 20 mL was aspirated and sent for cytology. Grossly right adnexal pedunculated mass arising from right ovary of 8 × 6 cm (Fig. 1) was seen. The mass was firm-to-hard with smooth outer surface, which was excised. Left ovary was bulky with cyst of 2 × 2 cm, which was enucleated. Uterus and bilateral fallopian tubes were normal. No peritoneal deposits and no

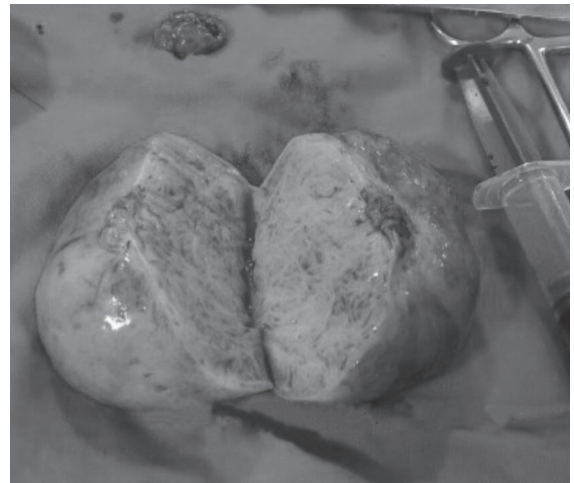
Assistant Professor

Department of Obstetrics and Gynaecology, All India Institute of Medical Sciences, Raipur, Chhattisgarh, India

**Corresponding Author:** Vinita Singh, Assistant Professor Department of Obstetrics and Gynaecology, All India Institute of Medical Sciences, Raipur, Chhattisgarh, India, Phone: +91-8518881708, e-mail: ddvinitasingh@gmail.com



**Fig. 1:** Fibroma of right ovary (8 × 6 cm)



**Fig. 2:** Cut section of fibroma of right ovary

lymph nodes were palpable. Omental biopsy was done though it showed no deposits. Mass was sent for histopathological examination. Cut section of mass was solid, and hard with whorled appearance (Fig. 2). Histopathology confirmed the diagnosis of ovarian fibroma, and the absence of malignant cells and a diagnosis of fibroma of right ovaries were given and left ovarian corpus luteal cyst was diagnosed. A meticulous search was made for any skin lesion or bony lesions, but no lesions could be detected. The patient stood the procedure well and was discharged on the 4th postoperative day.

## DISCUSSION

Fibromas and thecomas belong to a spectrum of benign ovarian tumors that are derived from ovarian stroma. Fibromas are the most common sex cord tumors and account for approximately 3 to 4% of all ovarian neoplasms.<sup>9</sup> Ovarian fibromas are almost always benign. Very rarely, fibromas without any atypical features are associated with peritoneal implants.<sup>10</sup> Fibromas are usually solid, spherical, slightly lobulated, encapsulated, gray-white masses covered by a glistening, intact ovarian serosa.<sup>11</sup> Fibromas should be both grossly and microscopically differentiated from thecoma and Brenner and Krukenberg tumors. Fibromas are solid, firm, and uniformly white, while thecomas have a yellow color in the cutting surface, an important feature in the differential diagnosis with fibroma. Brenner and Krukenberg tumors were excluded by negative immunoreactivity for keratin and epithelial membrane antigen.<sup>12</sup>

Ovarian fibromas are important from an imaging standpoint because they appear as solid masses, thereby mimicking malignant neoplasms.<sup>13</sup> Diagnosis is essentially clinical. Cytomorphology of the fluids and serum CA125 levels may be used to rule out malignant nature of the lesion. The workup should include ultrasound of

the pelvis, CT of the chest, abdomen and pelvis, magnetic resonance imaging of the pelvis, sampling of the pleural as well as the ascitic fluid, and serum markers of malignancy like CA125.<sup>14,15</sup> The CECT is helpful in delineating the tumor, its origin, and preservation of fat planes. Fibroma should be differentiated from stromal hyperplasia and fibrothecoma. On CT, fibroma appears as diffuse slightly hypoattenuating masses with very slow and poor enhancement after administration of contrast media.<sup>16,17</sup> Diagnosis is confirmed only on histopathology. Surgical removal of these solid ovarian tumors is recommended because of the low probability of malignancy and recurrence.<sup>18</sup> Laparoscopic-assisted vaginal hysterectomy can also be done, the tumor being removed in an endobag.<sup>19</sup> Salpingo-oophorectomy can be considered in perimenopausal or postmenopausal women, and cystectomy should be performed in young females.

## CONCLUSION

Ovarian fibromas are benign tumors of the ovary, difficult to diagnose preoperatively, and can clinically and biochemically mimic ovarian cysts, tubo-ovarian mass, uterine myoma, or ovarian malignancy. Also, fibroma must be distinguished from several nonneoplastic ovarian processes, specifically massive edema, fibromatosis, and stromal hyperplasia. Imaging is helpful to diagnose, but histopathology can only confirm the diagnosis. Treatment usually consists of surgical resection either by laparotomy or laparoscopic approach.

## REFERENCES

1. Sivanesaratnam V, Dutta R, Jayalakshmi P. Ovarian fibroma – clinical and histopathological characteristics. *Int J Gynaecol Obstet* 1990 Nov;33(3):243-247.
2. Tărcoveanu E, Niculescu D, Bradea C, Dimofte G, Vasilescu A, Ferariu D, Crumpei F. Incidence and management of the

- ovarian fibroma and thecoma. Experience of the First Surgical Clinic Ia i. *Chirurgia (Bucur)* 2006 May-Jun;101(3):325-330.
3. Tavassoli, FA.; Mooney, E.; Gersell, DJ.; McCluggage, WG.; Konishi, I. Sex cord-stromal tumors. In: Tavassoli FA, Devilee P, editors. *Pathology and genetics of tumors of the breast and female genital organs*. Lyon, France: IARC Press; 2003. p. 146.
  4. Mircea R, Anton E, Anton C, Tarniceriu C, Nedelcu AH, Pricop FZ. Specific features of the stromal ovarian tumors. *Rev Med Chir Soc Med Nat Iasi* 2012 Oct-Dec;116(4):1123-1130.
  5. Chechia A, Attia L, Temime RB, Makhlouf T, Koubaa A. Incidence, clinical analysis, and management of ovarian fibromas and fibrothecomas. *Am J Obstet Gynecol* 2008 Nov;199(5):473.e1-473.e4.
  6. Nocito AL, Sarancone S, Bacchi C, Tellez T. Ovarian thecoma: clinicopathological analysis of 50 cases. *Ann Diagn Pathol* 2008 Feb;12(1):12-16.
  7. Stephenson WM, Laing FC. Sonography of ovarian fibromas. *AJR Am J Roentgenol* 1985 Jun;144(6):1239-1240.
  8. Saul PB. Sex cord stromal tumors. *Clin Obstet Gynecol* 1985 Dec;28(4):839-846.
  9. Schwartz RK, Levine D, Hatabu H, Edelman RR. Ovarian fibroma: findings by contrast-enhanced MRI. *Abdom Imaging* 1997 Sep-Oct;22(5): 535-537.
  10. Young, RH.; Scully, RE. Sex cord-stromal, steroid cell and other ovarian tumours with endocrine, paraendocrine and paraneoplastic manifestation. In: Kurman RJ, editor. *Blausteins pathology of the female genital tract*. 5th ed. India: Springer Private Limited; 2004. p. 923-925.
  11. Crum, CP. The female genital tract. In: Kumar V, Abbas AK, Fausto N, editors. *Robbins and cotran pathologic basis of disease*. 7th ed. Philadelphia: WB Saunders; 2004. p. 1059-1117.
  12. Bjorkholm E, Silfversward C. Theca-cell tumors: clinical features and prognosis. *Acta Radiol Oncol* 1980 Feb;19(4):241-244.
  13. Souza LRMF, Faintuch S, Goldman SM, Louveira MH, Ajzen SA, Szejnfeld J. Avaliação por ressonância magnética de massas pélvicas. *Rev Imagem* 2003;25(1):5-11.
  14. Abad A, Cazorla E, Ruiz F, Aznar I, Asins E, Llixiona J. Meigs' syndrome with elevated CA 125: case report and review of literature. *Eur J Obstet Gynecol Reprod Biol* 1999 Jan;82(1): 97-99.
  15. Nemeth AJ, Patel SK. Meigs syndrome revisited. *J Thorac Imaging* 2003 Apr;18(2):100-103.
  16. Bazot M, Ghossain MA, Buy JN, Deligne L, Hugol D, Truc JB, Poitout P, Vadrot D. Fibrothecomas of the ovary: CT and US findings. *J Comput Assist Tomogr* 1993 Sep-Oct;17(5):754-759.
  17. Moon WJ, Koh BH, Kim SK, Kim YS, Rhim HC, Cho OK, Hahm CK, Byun JY, Cho KS, Kim SH. Brenner tumor of the ovary: CT and MR findings. *J Comput Assist Tomogr* 2000 Jan-Feb;24(1):72-76.
  18. Leung SW, Yuen PM. Ovarian fibroma: a review on the clinical characteristics, diagnostic difficulties and management option in 23 cases. *Gynecol Obstet Invest* 2006 Jun;62(1):1-6.
  19. Son CE, Choi JS, Lee JH, Jeon SW, Hong JH, Bae JW. Laparoscopic surgical management and clinical characteristics of ovarian fibromas. *J Soc Laparoendosc Surg (JLS)* 2011 Jan-Mar;15(1):16-20.