

Modified Two-corner Raz Suspension Procedure for Cystocele Repair: A Novel Technique

¹Vineet V Mishra, ²Nilesh L Goraniya, ³Sumesh D Choudhary, ⁴Urmila Sharma, ⁵Pradeep J Bandwal
⁶Tanvir Tanvir, ⁷Ritu Agarwal

ABSTRACT

Introduction: Prolapse of anterior vaginal wall is a common problem in both perimenopausal and postmenopausal women. In past 200 years, surgical management of cystocele has undergone many changes from Kelly's plication to mesh reinforcement but none of these procedures proved to be 100% effective. Modified two-corner Raz suspension procedure (MTCRSP) can be used for the treatment of POP-Q (pelvic organ prolapse quantification) stage II to IV anterior vaginal wall prolapse (AVP).

Objectives: To assess the effectiveness of modified two-corner Raz suspension procedure (MTCRSP) in long-term success for cystocele repair and its effect on quality of life.

Study design: A hospital-based prospective study.

Materials and methods: Twelve patients underwent modified two-corner Raz procedure and were followed postoperatively for a period of 1 year at regular intervals. During follow-up, we assessed the degree of prolapse by POP-Q, quality of life, and sexual dysfunction.

Results: Preoperatively, 3 out of 12 (25%) patients had stage II, five had (41.66%) stage III, and four (33.33%) had stage IV prolapse. Postoperatively, at 1 month follow-up, one (8.33%) patient developed stage II anterior wall prolapse, which progressed to stage IV prolapse at 3 months. Two more patients developed stage II prolapse at 3-month follow-up. Failure rate at the end of 1 year was 25% (3/12). Prolapse quality of life (PQOL) improved in 10 out of 12 (83.33%) patients. While PGII (patient global impression of improvement) score improved in 11 out of 12 (91.66%) women.

Conclusion: Modified two-corner Raz suspension procedure is an effective technique with long-term success in stage II and III prolapse but a limited success in stage IV AVP.

Keywords: Cystocele, POP-Q, Quality of life, Raz suspension procedure, Urinary retention.

How to cite this article: Mishra VV, Goraniya NL, Choudhary SD, Sharma U, Bandwal PJ, Tanvir T, Agarwal R. Modified

Two-corner Raz Suspension Procedure for Cystocele Repair: A Novel Technique. *J South Asian Feder Obst Gynae* 2016;8(2):130-135.

Source of support: Nil

Conflict of interest: None

Date of received: 2 Nov 2015

Date of acceptance: 20 Feb 2016

Date of publication: April 2016

INTRODUCTION

With the increase in life expectancy, prevalence of menopausal problems tend to rise, and uterovaginal prolapse is one of the most common of these problems. Lifetime risk of surgical correction of prolapse in USA at the age of 80 is 11.1, and 30% of these patients require second surgery for the same problem.¹ Anterior vaginal wall prolapse (AVP) is considered to be the most common prolapse in hysterectomized and non-hysterectomized females and its treatment remains a challenge for both gynecologists and urologists.

In 1980, Dr. Shlomo Raz introduced four-corner bladder suspension for the treatment of stress urinary incontinence (SUI) and cystocele stage II and III. This can be done as an isolated procedure or may be combined with vaginal hysterectomy or anterior and posterior repair.² However, the Raz two-corner suspension technique was used for the treatment of SUI only. Since the last 15 years, sling surgery has replaced Raz procedure for the treatment of SUI. We modified the Raz two-corner procedure for treatment of POP-Q (pelvic organ prolapse quantification) stage II to IV AVP. The aim of our study was to assess the effectiveness of this procedure in decreasing the recurrence rate of cystocele and its long-term complications.

MATERIALS AND METHODS

Twelve patients with stage II to IV cystocele underwent modified two-corner Raz suspension procedure (MTCRSP) at the Institute of Kidney Disease and Research Centre (IKDRC) from March 2013 to March 2014 and were followed up prospectively for 1 year.

The study was approved by the local ethical committee and informed consent was obtained from all the participants.

¹Professor and Head, ^{2,4}Fellow, ³Assistant Professor, ⁵⁻⁷Senior Resident

¹⁻⁷Department of Obstetrics and Gynecology, Smt. GR Doshi and Smt. KM Mehta Institute of Kidney Diseases and Research Center and Dr. HL Trivedi Institute of Transplantation Sciences Ahmedabad, Gujarat, India

Corresponding Author: Vineet V Mishra, Professor and Head Department of Obstetrics and Gynecology, Smt. GR Doshi and Smt. KM Mehta Institute of Kidney Diseases and Research Center and Dr. HL Trivedi Institute of Transplantation Sciences Civil Hospital Campus, Ahmedabad, Gujarat, India, Phone: +917922687038, e-mail: vineet.mishra.ikdrc@gmail.com

Inclusion criteria were stage II to IV AVP with lateral and/or central fascial defects. Exclusion criteria were previous retropubic suspension, lower urinary tract obstruction, stage I prolapse, senile vaginitis, and cystocele with transverse fascial defect.

Preoperative evaluation included a detailed history, general physical and local examination, stage of prolapse assessment by POP-Q, site of fascial defects, urine routine and microscopic examination, urine culture, assessment of post-voidal residual urine, examination for simultaneous stress urinary incontinence by cough test after reducing the prolapse part, Bonney's test (manual deviation of bladder neck to ascertain the presence of SUI and to predict outcome of sling surgery), and Q tip test. Uroflowmetry and urodynamic studies were also done in certain cases for associated urinary incontinence.

Preoperative and postoperative condition of the patients was assessed by a validated patient self-assessment questionnaire that included PQOL (prolapse quality of life) and PISQ-IR [sexual function for women with POP (pelvic organ prolapse), urinary incontinence/fecal incontinence] to determine sexual dysfunction in women with POP. PGII (patient global impression of improvement) questionnaire was used to determine the score that best described the patient's postoperative condition as compared to the preoperative condition, and the Incontinence Impact Questionnaire (IIQ-7) was used to assess the presence and severity of incontinence.

The original Raz two-corner bladder neck suspension was used for the treatment of SUI only by correcting urethrovesical angle in which small incisions of 2 cm were made on either side of the bladder neck. Two prolene sutures were used to take helical stitches on urethropelvic ligament and vaginal wall excluding vaginal epithelium on either side, which were then transferred to abdominal suprapubic incision with a double-pronged needle.

Raz four-corner suspension was used to correct grade I to III cystocele associated with SUI in which four prolene sutures were used. Bladder neck suspension was carried out by using two No. 1 prolene helical stitches through urethropelvic ligament and vaginal wall. Cystocele suspension was performed by placing similar three to four helical stitches laterally through proximal vaginal wall, cardinal ligaments, and pubocervical fascia.

We did a modification of the Raz two-corner suspension technique to repair only cystocele by using two prolene sutures. In our modification, we suspended vaginal wall and pubocervical fascia retropubically to rectus sheath, so that the rectus sheath acts as an anchor for cystocele. We did not include bladder neck suspension in contrast to original Raz's two-corner and four-corner suspension. So, this modified procedure was not suitable for the treatment of SUI. The associated incontinence was

treated by a transobturator (TOT) tape or tension-free vaginal tape. All surgeries were performed by a single experienced surgeon (Vineet V Mishra).

Procedure

Catheterization with 16 F Foley's catheter was done. Vaginal wall was infiltrated with 1:200,000 epinephrine solution and a vertical midline incision was given on proximal 2/3rd of anterior vaginal wall followed by lateral dissection bilaterally till thick pubocervical fascia was identified. Two small incisions 5 cm apart and 1 cm above the pubic tubercle were made. Retropubic blunt dissection was done close to bladder neck bilaterally and retropubic fascia was opened using Mayo's scissors. Three to four helical stitches were taken using No. 1 prolene on either side including pubocervical fascia and 2/3rd of vaginal wall thickness (Fig. 1). Stamey's 15° needle was passed from suprapubic incisions through retropubic fascia under finger guidance to avoid injury to visceral organs so as to bring all prolene ends to the abdominal incision (Figs 2 and 3). Cystoscopy was done at this stage to rule out bladder injury. Redundant vagina was preserved and bilateral cardinal ligaments were not

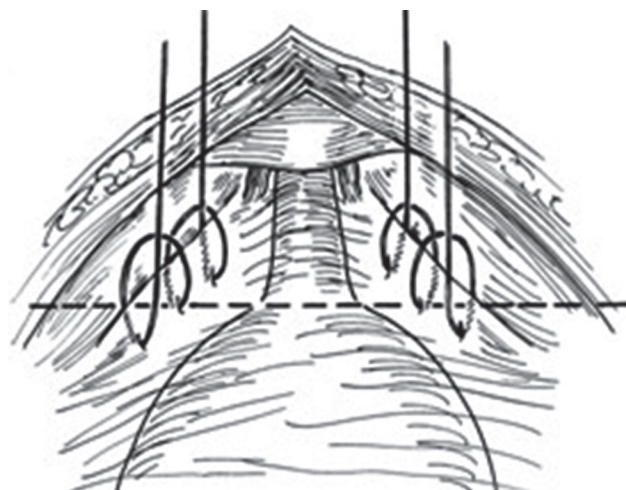


Fig. 1: Helical stitches using prolene suture

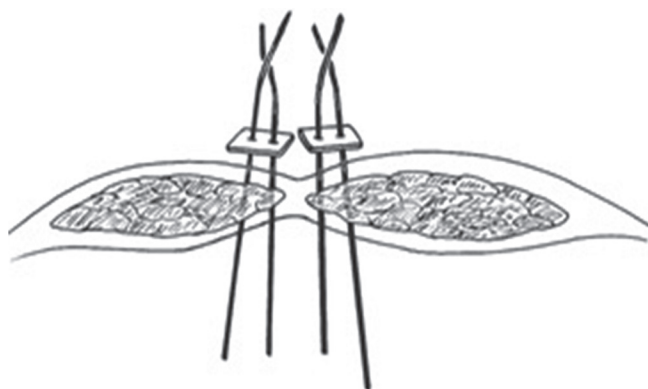


Fig. 2: Prolene ends brought out suprapubically

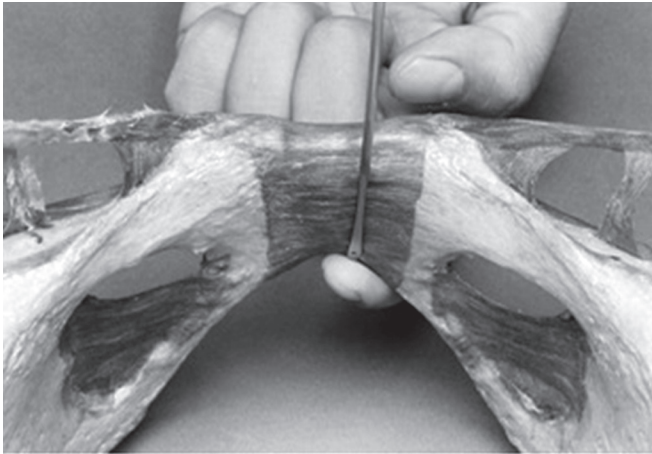


Fig. 3: Passage of Stamey's needle under finger guidance

included as in the original four-corner Raz procedure. Vaginal wall sutured with polyglactine 2-0 interrupted sutures.

Appropriate tension was given on prolene to lift the anterior vagina and tied on rectus sheath. Ends of prolene crossed over on opposite sides at the abdominal end and tied. A cystoscope sheath was placed via urethra into bladder. If the entire sheath could not be pushed downward to reproduce bladder neck hypermobility, then this degree of lift was considered to be optimal, but if the sheath hit forward anteriorly toward pubis then suspension was overcorrected. Skin closure was done with polyglactine 2-0.

Postoperatively, catheter was removed after 24 hours and antibiotics were administered for 3 days. Those, who were unable to void were recatheterized and were taught pelvic floor exercises followed by a voiding trial after 1 week. If retention persisted, clean intermittent catheterization (CIC) was taught and reassessment done after a month.

The duration of surgery, any type of intraoperative (bladder perforation, hemorrhage), immediate (hematoma, secondary hemorrhage), or late postoperative (wound infection, urinary tract infection, urinary retention) complications were recorded.

Postoperatively, patients were followed up at 1, 3, and 6 months, and at 1 year. During follow-up, patients were enquired regarding any voiding difficulties and physical examination was done to assess objective improvements, which included assessment of prolapse by POP-Q. Anatomical failure was considered when prolapse of stage II or more was found during follow-up.

RESULTS

The age of the patients ranged from 40 to 80 years with a mean of 54.31 years. Nine (75%) were postmenopausal. Mean parity was 4.2. Five (41%) women had a history of vaginal hysterectomy, out of which three hysterectomies were for prolapse and two for DUB (dysfunctional uterine bleeding), five had atrophic vagina, two had SUI, and none had urge incontinence preoperatively.

Modified two-corner Raz suspension procedure was carried out along with concomitant procedures if prolapse of other vaginal part was also present. Out of 12 patients, 4 (33.33%) underwent repair with only MTCRSP, 1 underwent concomitant sacrospinous fixation and 4 underwent simultaneous colpoperineorrhaphy (Table 1).

One patient who underwent hysterectomy with MTCRSP for stage IV prolapse developed stage II AVP at 1 month, which later progressed to stage IV prolapse at 3 months' follow-up. Two other patients developed stage II prolapse after 3 months. So, at the end of 1 year, total three (25%) patients had anatomic failure. Two out of these three patients had stage IV prolapse preoperatively. So, recurrence rate in stage IV prolapse after

Table 1: Preoperative assessment and procedure done

Patient	H/o Hysterectomy	Incontinence?	POP-Q stage of cystocele	Fascial defects	Other site prolapse	Other combined procedure
1	Yes	No	II	L*	No	–
2	Yes	No	II	L	No	–
3	Yes	No	IV	C+L	Rectocele	Sacrospinous fixation
4	Yes	No	II	C+L	No	–
5	No	Yes	III	C#	No	TOT with hysterectomy
6	No	Yes	III	C	No	TOT with hysterectomy
7	Yes	No	III	C+L	No	–
8	No	No	IV	C+L	Rectocele	Hysterectomy with colpoperineorrhaphy
9	No	No	IV	C+L	Rectocele	Hysterectomy with colpoperineorrhaphy
10	No	No	III	C+L	Rectocele	Hysterectomy with colpoperineorrhaphy
11	No	No	III	C+L	No	Hysterectomy
12	No	No	IV	C+L	Rectocele	Hysterectomy with MaCall's culdoplasty and colpoperineorrhaphy

#C: Central defects; *L: Lateral defects

MTCRSP was 50% (two out of four) (Table 2). Subjective improvement was noted in 91% and objective improvement in 75% regarding prolapse symptomatology. One patient with recurrent stage IV prolapse underwent surgery for vault suspension by sacrocolpopexy at 6 months.

Failure rate of MTCRSP in patients with combined central and lateral defect was 25%. Out of two patients with isolated central defect, one developed recurrence, while out of 10 patients with lateral defect cystocele, only two had recurrence (success rate 80%).

In 1-year duration, three patients developed posterior vaginal wall prolapse out of which one had stage III rectocele at 3 months' follow-up and two had stage I rectocele at 6 months' follow-up.

Three (25%) patients developed urinary retention postoperatively. After 1 week of recatheterization and pelvic floor physiotherapy, all three patients voided normally without significant post-void residual urine. One out of these patients developed intermittent urinary retention for a period of 8 months for which clean intermittent catheterization was taught. Micturition cystourethrogram (MCU) suggested disturbed urethrovesical angle in that patient, which was managed conservatively.

Mean operative time for isolated anterior vaginal wall suspension was 45 ± 6 minutes. Average hospital stay was 3.5 days (2–7 days).

None of the patients had vesicovaginal fistula or urge incontinence postoperatively. There were no intraoperative complications in any of the patients. No perforation of bladder, retropubic hematoma, or need of blood transfusion was noted. No patient had postoperative infection or erosion of prolene suture outside the vagina. None of the patients developed urinary tract infection (UTI) or required release of prolene suture in case of retention. There were no complaints of dyspareunia in women who were sexually active.

Quality of life as assessed by the PQOL questionnaire improved significantly in 10 out of 12 (83.33%) patients with a score of 2.0 (2 = mostly satisfied). Sexual dysfunction according to PISQ-IR improved in all seven (100%) sexually active women. According to PGII questionnaire, 10 out of 12 (83.33%) patients selected a score of 1 (much better), one selected a score of 3 (little better), and a patient

with recurrent stage IV prolapse selected a score of 5 (little worse) at the end of 1 year.

Two patients who underwent TOT procedure for incontinence had improved IIQ-7 score. Remaining 10 patients who were continent preoperatively had no complain of incontinence and IIQ-7 score remained the same.

DISCUSSION

There is no literature regarding retropubic suspension technique for treatment of isolated anterior vaginal wall prolapse without SUI. Currently, there is a decline in the number of articles related to the Raz procedure, which suggests that less number of Raz procedures are being carried out throughout the world.

Modified two-corner Raz suspension procedure is an effective technique for stage II and III AVP with guarded success in stage IV prolapse. Better outcome was noted in case of posthysterectomized patients with cystocele. In MTCRSP, bladder support was achieved by strengthening the pubocervical fascia and suspending it to the rectus sheath just above the pubic tubercle in suprapubic area. Rectus sheath, near its insertion to the pubic bone, acts as a firm, immobile structure, thus providing a static suspension independent of the patient's day-to-day activities.

Some authors believe that the Raz suspension procedure disrupts the horizontal axis of proximal 2/3rd of the vagina, which may predispose to enterocele formation and vault prolapse as in Burch's procedure.³ In our study, we noted that over-correction of anterior segment causes modification of line of force and pelvic statics. Two women developed rectocele stage I, which was diagnosed on routine follow-up examination and managed conservatively. One woman developed stage III rectocele with enterocele at 3 months postoperatively.

There was a failure rate of 50% in patients with stage IV prolapse with MTCRSP. The cause of failure might be tissue necrosis, suture pulled out from vaginal wall, or inadequate mobilization of bladder and pubocervical fascia. Prior to attempting suspension of anterior vaginal wall, extensive mobilization of bladder is essential for successful outcome.

Our study analyzed the effectiveness of MTCRSP in the management of cystocele and its long-term outcome. Success rate was 75% without the use of any mesh products at the end of 1 year. No long-term retention needing urethrolisis was encountered. No major intraoperative or postoperative complications were noted. So, we conclude that MTCRSP decreases the recurrence rate of cystocele and long-term complications. However, MTCRSP is not helpful for the treatment of SUI as paraurethral supports are not included. So, the concomitant anti-incontinence procedure is required

Table 2: Relation between preoperative and postoperative staging at the end of 1 year

Follow-up staging	Preoperative stage II (n=3)	Preoperative stage III (n=5)	Preoperative stage IV (n=4)
No prolapse	3	4	2
Stage I	–	–	–
Stage II	–	1	1
Stage III	–	–	–
Stage IV	–	–	1

to treat associated SUI. Potential benefit of MTCRSP is the use of native tissue, thus avoiding complications of mesh, such as erosion, pelvic pain, vaginal atrophy, and aging of tissue.⁴

Raz reported on a long series of patients with grade II and III cystocele who underwent four-corner suspension. Mean duration of follow-up in his study was 2 years. Success rate for moderate cystocele was 98%.⁵ In our study, failure rate for cystocele repair was 25%. Our study included even stage IV prolapse while Raz's study included only up to stage III or less prolapse.

Agatstein and Shlomo Raz in their published series of 82 patients performed four-corner Raz procedure in 33 patients with grade I to III cystocele but did not analyze the success rate in terms of recurrent prolapse of anterior vaginal wall.² Miyazaki et al in a study of 27 patients with severe cystocele who underwent four-corner Raz procedures did not find satisfactory results for severe cystocele on long-term follow-up of 4 years. Failure rate was 59%.⁶ Kohli et al observed 33% cystocele recurrence rate after four-corner needle suspension as compared to only 7% after anterior colporrhaphy technique of cystocele repair at the end of 1 year.⁷ They showed that the result of anterior colporrhaphy were still good.

In our study, three patients developed stage II or more severe vault prolapse. In another study by Raz, there was 7.5% failure rate for grade II cystocele but data regarding vault prolapse were not available.⁵ A comparative study of 52 patients between Raz four-corner procedure *vs* conventional Nicholas techniques of cystourethrocele repair conducted by V Scotto Di Palumbo showed a higher anatomic correction of cystocele in four-corner Raz procedure than the Nicholas technique at the end of 1 year. Study showed that the risk of rectocele in four-corner Raz procedure was 17.9% as compared to 5.8% in the Nicholas technique. However, risks became lower in long-term follow-up.⁸ Our study showed results comparable to the above study; anatomic success rate for cystocele repair was 75%, while significant rectocele recurrence was seen only in 9% cases.

Limitations of our study were a small sample size, short duration of follow-up (1 year), and a wide range of age group from 35 to 80 years. Our technique involved placement of helical stitches through vaginal wall close to each other, while Raz showed diagrammatic placement of helical stitches in the vagina in four-corner needle suspension quite separate from each other.⁹ Our technique of lateral defect repair did not involve attachment of pubocervical fascia to arcus tendineus. By involving cardinal ligaments in cystocele repair, recurrence rate due to transverse defect can be minimized and success rate can be improved. It cannot treat SUI as paraurethral ligaments are not included in helical stitch.

According to Menefee SA et al, anatomic failure of anterior colporrhaphy for cystocele repair was 58% in their comparative study of mesh repair and anterior colporrhaphy.¹⁰ Hiltunen et al noted recurrence rate of 38.5% after 1 year of anterior colporrhaphy for prolapse in their study of 92 patients.¹¹ All the studies showed a lower success rate with conventional methods. Success rate of transabdominal cystocele repair by wedge colpectomy at 3 year follow-up was 95.5 and 76.5% in first- and second-degree prolapse respectively but stage IV prolapse was not included in the study.¹²

Suspension of vagina to fixed or rigid anatomical structures provides a longstanding anatomic support and higher success rate, simultaneously improving the quality of life and sexual dysfunction. Hence, suspension of vagina to rectus sheath can be applied in the future as a treatment of cystocele. Shull et al in his study of 62 women with paravaginal defect repair showed 33% failure rate for AVP.¹³ Benson et al showed that the mean time of recurrence after paravaginal repair through vaginal route was 11.2 months. Reoperation rate was 29% in the vaginal group.¹⁴ Failure rate for paravaginal defect repair in our study was 20%. Our study had higher success rate and lower reoperation rate for isolated paravaginal repair as compared to other studies.

CONCLUSION

Modified two-corner Raz suspension procedure seems to be able to correct a majority of defects of anterior vaginal wall prolapse with good long-term outcome and anatomic restoration. However, further large studies are required to establish the feasibility and effectiveness of this procedure in anterior vaginal wall prolapse.

REFERENCES

1. Oslen AL, Smith VJ, Bergstrom JO, Clark AL. Epidemiology of surgically managed pelvic organ prolapse and urinary incontinence. *Am J Obstet Gynecol* 1997 Apr;89(4):501-506.
2. Agatstein EH, Raz S. The Raz Bladder suspensions treatment of stress urinary incontinence: 10 years personal experience. *TOUNJ* 2014;7:86-90.
3. Bruce RG, El Galley RE, Galloway NT. Paravaginal defect repair in the treatment of female stress urinary incontinence and cystocele. *Urology* 1999 Oct;54(4):647-651.
4. US Food and Drug Administration. FDA Public Health Notification: serious complications associated with transvaginal placement of surgical mesh in repair of pelvic organ prolapse and stress urinary incontinence; 2011 July.
5. Raz S, Little ANA, Juma S, Sussman EM. Repair of severe anterior vaginal wall prolapse (grade IV) urethrocyctocele. *J Urol* 1991 Oct;146(4):988-992.
6. Miyazaki FS, Miyazaki DW. Raz four corner suspension for severe cystocele: Poor results. *Inturogynecol J* 1994 Apr; 5:94-97.
7. Kohli N, Sze EHM, Todd WR, Karram MM. Incidence of recurrent cystocele after anterior colporrhaphy with and

- without concomitant transvaginal needle suspension. *Am J Obstet Gynecol* 1996 Dec;175(6):1476-1482.
8. Scotti Di Palumbo V. Four corner bladder and urethral retropubic suspension versus anterior colporrhaphy in the correction of stress urinary incontinence with urethrocyctocele 3-4. Randomized clinical Trial. *Urogynecol Int J* 2003;17(1): 57-68.
 9. Raz S, Sussman EM, Erickson Dr Vaginal repair of high grade cystocele. *Contemp Urol* 1991 May;3(5):80-94.
 10. Menefee SA, Dyer KY, Lukacz ES, Simsiman AJ, Lubner KM, Nguyen JN. Colporrhaphy compared with mesh or graft-reinforcement vaginal paravaginal repair for anterior vaginal wall prolapse. *Obstet Gynecol* 2011 Dec;118(6):1337-1344.
 11. Hiltunen R, Nieminen K, Takala T, Heiskanen E, Merikari M, Niemi K, Heinonen PK. Low weight polypropylene mesh for anterior vaginal wall prolapse: A randomized control trial. *Obstet Gynecol* 2007 Aug;110(2 Pt 2):455-462.
 12. Quadri G, Magatti F, Belloni C, Mattioli G. Transabdominal repair of cystocele by wedge colpectomy during combined abdominovaginal surgery. *Int Urogynecol J Pelvic Floor Dysfunct* 1997;8(5):278-283.
 13. Shull RL, Benn SJ, Khuel TJ. Surgical management of prolapse of anterior vaginal segment: an analysis of support defects, operative morbidity and anatomic outcome. *Am J Obstet Gynecol* 1994 Dec;171(6):1429-1439.
 14. Benson JT, Lucente V, McClellan E. Vaginal versus abdominal reconstructive surgery for the treatment of pelvic support defects: a prospective randomized study with long term outcome evaluation. *Am J Obstet Gynecol* 1996 Dec;175(6): 1418-1422.