

CASE REPORT

Uterine Perforation and Extensive Large Bowel Injury

Jyoti Ramesh Chandran

ABSTRACT

Unsafe abortion represents a preventable yet major cause for maternal mortality in India. Complications may occur in these cases and ultimately require tertiary care. Large bowel injury is a rare complication and can occur when the uterus is perforated, allowing the instrument to pierce the underlying structures. Here, we discuss a case of a woman who sustained injury to large bowel during second trimester medical termination of pregnancy (MTP) and had to undergo complete large bowel resection.

Keywords: Large bowel injury, Mifepristone, Misoprostol, Second trimester medical termination of pregnancy.

How to cite this article: Chandran JR. Uterine Perforation and Extensive Large Bowel Injury. *J South Asian Feder Obst Gynae* 2015;7(3):225-226.

Source of support: Nil

Conflict of interest: None

Date of received: 7 September 2015

Date of acceptance: 20 September 2015

Date of publication: December 2015

INTRODUCTION

Unsafe abortion represents a preventable yet major cause for maternal morbidity and mortality in India. Incidence of uterine perforation varies from 0.4 to 15% per 1,000 abortions as reported by different studies.¹ However, large bowel injury has not been reported so far. Extensive injury to the uterus and bowels may necessitate laparotomy with hysterectomy and bowel resection and anastomosis respectively to save the life of patients.²

CASE REPORT

A 19-year-old G2A1 was referred to our institute on Aug 3, 2011, following attempted evacuation and prolapsed large bowel mucosa following failed medical methods (multiple doses of vagina misoprostol) for second trimester medical termination of pregnancy (MTP) for fetal anomaly (Dandy-Walker malformation with sacral agenesis) by a gynecologist.

On examination, she was semiconscious, febrile having pulse 120/min and BP 100/60 mm Hg with severe pallor. Abdominal examination showed generalized tenderness with guarding and rigidity. Per vaginal examination revealed multiple loops of bowel mucosa inside the introitus. She was immediately taken for laparotomy with the help of surgeons.

OPERATIVE FINDINGS

There was hemoperitoneum about 300 ml. Uterus was 14 weeks size with a rent in right lateral wall extending up to the cornual region through which large intestinal mucosa measuring 2.65 meters length was protruding into the vagina. The origin of injury was the cecum through which the mucosa was sleeved out (Fig. 1). Mutilated fetus was found in the peritoneal cavity (Fig. 2). Total hysterectomy with right salpingo-oophorectomy

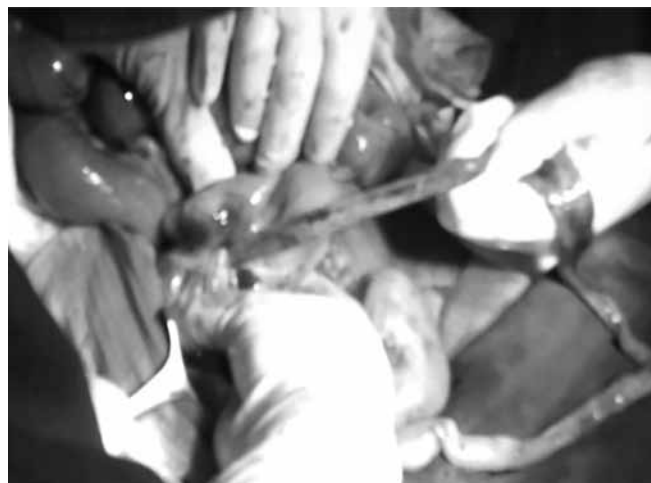

Fig. 1: Bowel mucosa traced to cecum

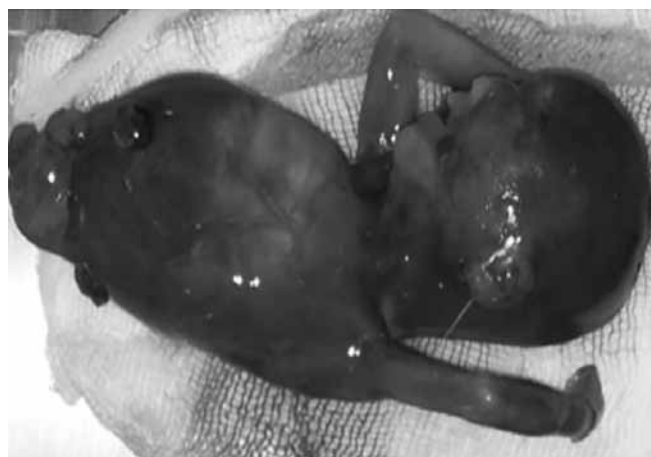

Fig. 2: Mutilated fetus

Additional Professor

Department of Obstetrics and Gynecology, Government Medical College, Calicut, Kerala, India

Corresponding Author: Jyoti Ramesh Chandran, Additional Professor, Department of Obstetrics and Gynecology Government Medical College, Calicut, Kerala, India, Phone: 9995353512, e-mail: drjyotichandran@gmail.com

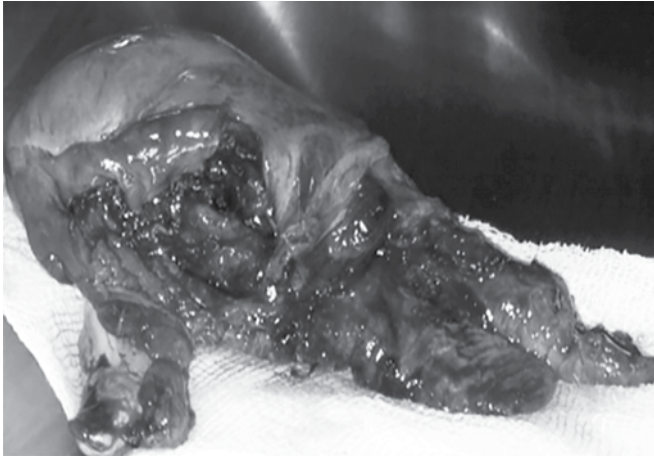


Fig. 3: Rent in uterus extending to cornual region

(Fig. 3) followed by resection of large bowel from cecum to sigmoid colon with ileal colostomy was done. Multiple blood and blood products were transfused intra- and postoperatively. Broad spectrum antibiotics and prophylactic anticoagulation was given. She was discharged on 25th postoperative day. Her ileostomy was closed 9 months after the primary surgery. She was

divorced by her husband and now lives in agony with constant gastrointestinal symptoms.

CONCLUSION

- Multiple vaginal applications of misoprostol makes the cervix and lower segment soft and liable to injury
- An alternative would be oral mifepristone (200–600 mg) followed by misoprostol after 48 hours and less frequent application of misoprostol.
- Utmost care should be taken while attempting evacuation in such cases.
- Spontaneous expulsion should be anticipated with oxytocin drip if necessary.

REFERENCES

1. Sedgh G, Henshaw S, Singh S, Ahman E, Shah IH. Induced abortion: estimated rates and trends worldwide. *Ancet* 2007 Oct 13;370(9595):1338-1345.
2. Gole GN, Santpur U, Kaul R. Severe intra-abdominal trauma in illegal abortion: a case report. *Int J Obstet Gynaec* 2012;6(3):1.