

## SURGICAL TECHNIQUE

# Laparoscopic Management of Interstitial Ectopic Pregnancies

<sup>1</sup>Gaurav S Desai, <sup>2</sup>Jessi Levi, <sup>3</sup>Shyam V Desai

## ABSTRACT

This illustration describes the successful laparoscopic management of interstitial ectopic pregnancy. Three women underwent laparoscopic excision for interstitial ectopic gestation. Mean operative time was  $49.4 \pm 8.4$  minutes (41-69 mins). Estimated blood loss was  $50 \pm 4$  ml. There were no intraoperative or postoperative complications. Duration of hospital stay was  $24 \pm 3$  hours. All patients are doing well on follow-up. The authors demonstrate the role of laparoscopic excision and conclude that this technique, when performed by experienced surgeons, allows for improved dexterity and is a safe and effective method in the management of interstitial ectopic pregnancy.

**Keywords:** Laparoscopy, Ectopic pregnancy, Interstitial pregnancy, Cornual excision.

**How to cite this article:** Desai GS, Levi J, Desai SV. Laparoscopic Management of Interstitial Ectopic Pregnancies. *J South Asian Feder Obst Gynae* 2014;6(3):163-166.

**Source of support:** Nil

**Conflict of interest:** None

## INTRODUCTION

Frequent locations of ectopic pregnancies include the ampullary or isthmic portions of the fallopian tubes. These account for 90% of ectopic gestations. Uncommonly, the gestational sac is found within the interstitium or the cornual region of the fallopian tube in about 2 to 5% of ectopic pregnancies.<sup>1-3</sup> This poses a diagnostic and a therapeutic dilemma for the clinician because these ectopic pregnancies are amenable to uterine rupture and catastrophic hemorrhage.<sup>4</sup> A reason is access of the growing gestational sac to the neighboring myometrial tissue and its blood supply which, in some cases, allows the pregnancy to progress into the second trimester.<sup>5,6</sup> The purpose of this report is to describe the detection

and evaluation of a interstitial ectopic gestation and its subsequent treatment with laparoscopic excision.

We reviewed records of three patients at our clinic who underwent laparoscopic excision of the interstitium for an ectopic pregnancy.

## CASE REPORTS

The authors conducted a retrospective study at two private medical centers. We performed a search of our electronic medical record database to identify patients undergoing laparoscopic surgery for interstitial ectopic pregnancy. All patients had a written and verbal informed consent. Between December 1991 and July 2014, a total of 2,234 laparoscopic procedures were conducted at the two institutions, of which 1023 were operative. Laparoscopic intervention was carried out for 587 ectopic pregnancies among whom three had interstitial location of the gestational sac. These three women (mean age: 28 years, range: 24-32 years) underwent laparoscopic salpingectomies for interstitial ectopic gestation at our institutions. Mean operative time was  $49.4 \pm 8.4$  minutes (41-69 mins). Average estimated blood loss was  $50 \pm 4$  ml (48-52 ml). There were no intraoperative or postoperative complications. Average duration of hospital stay was  $24 \pm 3$  hours. All patients are currently doing well on follow-up visits.

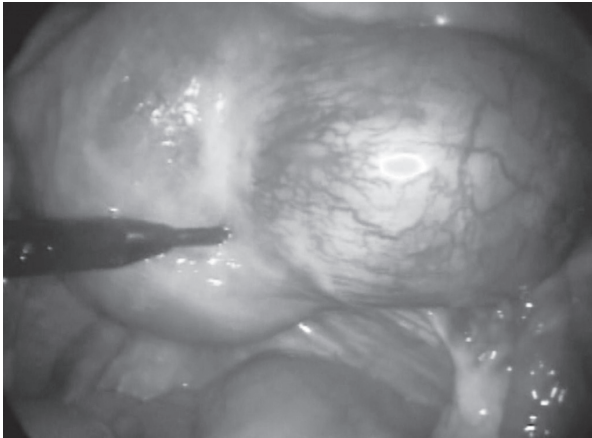
### Case 1

The patient was a 24-year-old gravida 4 para 1 living 1 with a history of three abortions. These consisted of two medical termination at 5.6 and 5.7 weeks, and a suction evacuation at 6 weeks with copper T insertion. The estimated gestational age of 4.2 weeks was confirmed by an ultrasonographic scan which showed a right interstitial ectopic gestation. She denied pain or bleeding per vaginam. Her medical and surgical histories were not informative and her obstetric history was notable only for an uncomplicated normal spontaneous vaginal delivery at term. She had no risk factors for ectopic pregnancy. Neither abdominal nor pelvic examination revealed any tenderness, her uterus was normal in size. Her beta-hCG a day prior to laparoscopy was 2531 and on postoperative day 1 and 7 was 543 and 373 mIU/l respectively. The patient was counseled on the findings and elected to proceed with laparoscopic management (Figs 1 to 5).

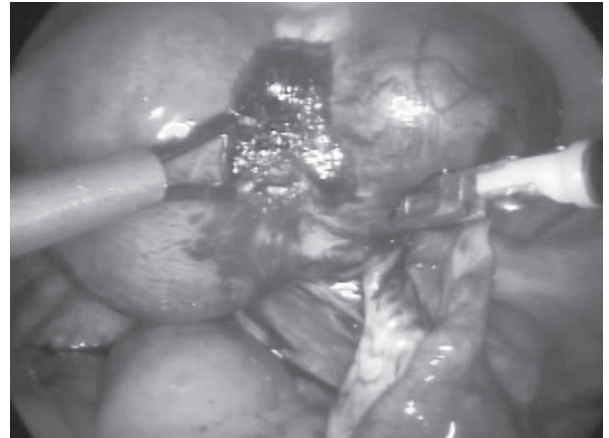
<sup>1</sup>Resident, <sup>2</sup>Consultant, <sup>3</sup>Professor

<sup>1-3</sup>Department of Obstetrics and Gynecology, Mothercare Nursing Home, Daftary's Total Care Clinic, Mumbai, Maharashtra India

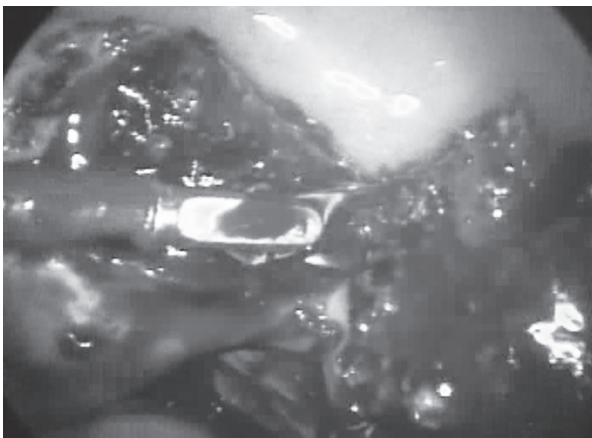
**Corresponding Author:** Gaurav S Desai, Resident Department of Obstetrics and Gynecology, Mothercare Nursing Home Daftary's Total Care Clinic, Mumbai, Maharashtra, India Phone: +91-9594597490, e-mail: gdesai83@gmail.com



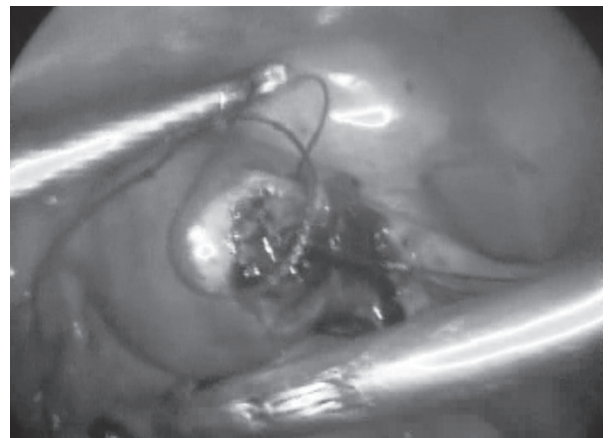
**Fig. 1:** Laparoscopic image of a right interstitial ectopic gestation in a 24-year-old woman. Adequate hemostasis was achieved with injection of adrenaline (as shown in the image)



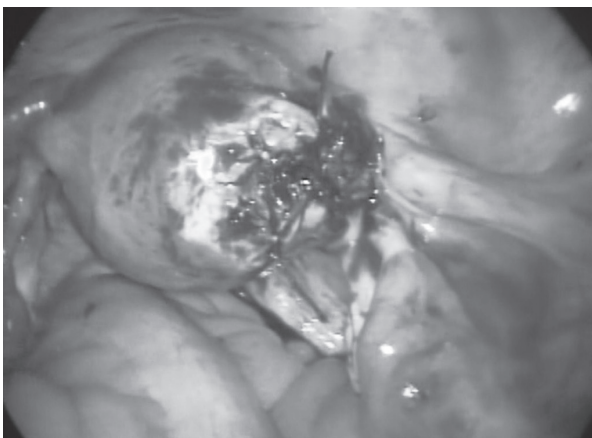
**Fig. 2:** Laparoscopic image shows cauterization of the base of ectopic gestational sac



**Fig. 3:** Laparoscopic surgery proceeds with cutting around the base of the ectopic pregnancy



**Fig. 4:** Laparoscopic image of the right border of the uterus showing the suturing of the bed of the excised sac. Vicryl suture material was used to approximate the defect caused after excision of the interstitial pregnancy



**Fig. 5:** Laparoscopic image of the sutured bed of the excised sac with complete hemostasis

### Case 2

A 28-year-old primigravida with known history of endocervicitis and a 4 cm right subserous fibroid complained of left-sided abdominal pain. A pelvic sonogram revealed a left-sided ruptured interstitial ectopic pregnancy consistent with a gestational age of 9.6 weeks. She revealed

a history of taking oral contraceptive medication for 2 years which she stopped recently. A beta-hCG done on the day of the laparoscopy was 979 and, on postoperative day 7 and 21 was 265 and <1.2 mIU/L respectively. One month hence, she underwent a hysterosalpingogram at our clinic which revealed an arcuate uterus and a patent right fallopian tube. She is keen on conception and is undergoing an intrauterine insemination.

### Case 3

A 32-year-old gravida 2 para 1 living 1 underwent a sonographic examination which revealed a left-sided interstitial ectopic pregnancy of 6.2 weeks gestational age. Her only significant history was that of fungal vaginitis treated subsequently and follicular studies for conception. The patient was counseled on the USG results and decided on a laparoscopic removal of her ectopic pregnancy. A beta-hCG done a day prior to the laparoscopic resection was 21,199 and on postoperative day 7, 10 and 17 was 6288, 1474 and 100.3 mIU/l respectively.

## Laparoscopy Protocol

All surgeries were performed by the senior surgeon (SVD), who has over 30 years of experience with laparoscopic pelvic surgery and who was assisted by another attending physician (JL, 25 years experience) and a senior resident (GSD). Informed consent was obtained in each case and the patient was made aware of the nature of the procedure. All pertinent medical records were reviewed meticulously to provide data for this report.

## Surgical Technique

Under general anesthesia, 16 Fr. patient was placed in the dorsal lithotomy position and a Foley catheter inserted. Abdominal and perineal parts were painted with savlon and povidone iodine solutions and draped. Suction curettage was performed to eliminate the possibility of a heterotopic pregnancy. A uterine manipulator was inserted into the uterus.

A primary port 10 mm incision was made infra-umbilically and pneumoperitoneum created with a Veress needle and carbon dioxide gas (flow rate: 4.5-5 l/min and pressure: 14 mm Hg). A trocar and cannula was put in place followed by insertion of a 30 degree laparoscope (Karl Storz Endoskope, Tuttlingen, Germany). Pelvic organs were assessed and location of the interstitial ectopic noted. Two secondary 5 mm ports were created and secondary trocar and cannulas inserted.

Uterus was anteverted and the surgeon in chief (SVD) injected a total of 15 ml of adrenaline (1:100000) into the entirety of the gestational sac and the surrounding myometrial tissue via a needle guided through the laparoscope. Complete blanching of the interstitial pregnancy was achieved. A bipolar cautery (Richard Wolf Medical Instruments, Vernon Hills, IL) was used to achieve hemostasis around the ectopic sac and a metzenbaum scissors (Karl Storz Endoskope, Tuttlingen, Germany) used to make a linear incision into the myometrium and tube around the sac. The ectopic sac was placed into a endo-bag and removed from the primary port. The bed of the myometrium was coagulated and sutured using 1-0 vicryl in a figure of 8 fashion. No myometrial defect was noted. All instruments were removed under vision as were the trocars and cannulas. The pelvis is lavaged with normal saline solution and hemostasis confirmed. The insufflated gas was made to escape and skin incisions closed with 2-0 ethilon. Dressing was one and once patient vital parameters stabilized they were shifted to the recovery room. The specimen was sent to histopathology and the diagnosis of an ectopic pregnancy confirmed.

## DISCUSSION

Diagnostic evaluation of interstitial ectopic pregnancy includes the use of ultrasonography, serial beta-hCG evaluation and to some extent laparoscopy.<sup>7,8</sup> In some cases, diagnosis of interstitial gestation is not confirmed until one inserts a laparoscope. Soriano et al published a series of 27 consecutive women with cornual pregnancy, 20 of whom underwent laparoscopy. Only 15 (55.6%) of the 27 pregnancies were diagnosed on transvaginal sonography before the therapeutic procedure.<sup>17</sup> The mainstay of management of interstitial ectopic gestation includes methotrexate therapy and surgery. Up until the early 21st century, surgical intervention included hysterectomy and resection via laparotomy.<sup>9-11</sup>

However, recent advances in endoscopic surgery coupled with the drawbacks in laparotomy have made techniques, such as laparoscopic resection, laparoscopic cornuostomy and hysteroscopic removal of interstitial ectopic tissue, the preferred approaches. Reports have also been put to print on the successful management of interstitial ectopic pregnancies with laparoscopic surgery, even in cases of rupture if accompanied with intraoperative autologous blood transfusion.<sup>12,13</sup>

Authors have suggested that the management depends on the size of the ectopic sac. In their series of five cases, Tulandi et al successfully used laparoscopy for interstitial pregnancy, including cornual excision in four patients and salpingotomy incision via the myometrium in the other.<sup>14</sup> Tulandi et al also stated that salpingotomy is appropriate for gestations of <3.5 cm, whereas cornual excision is recommended for gestations larger than 4 cm.<sup>14-16</sup> As in the reports by Grimbizis et al and Takeda et al, one of our patients presented with signs of ruptured interstitial pregnancy.<sup>12-13</sup> We followed the protocol of transfusing adequate volume of crossmatched blood and conducting the laparoscopic procedure with judicious supervision of her vital parameters. In some cases, diagnosis of interstitial gestation is not confirmed until one inserts a laparoscope.

Soriano et al published a series of 27 consecutive women with in pregnancy, 20 of whom underwent laparoscopy.<sup>17</sup>

Only 15 (55.6%) of the 27 pregnancies were diagnosed as a cornual pregnancy by transvaginal sonography before the therapeutic procedure.<sup>17</sup> Management of a ruptured interstitial pregnancy is more difficult as compared to tubal pregnancy because proper excision may not be possible. Further, the resection of an interstitial pregnancy differs from a tubal ectopic as far as the technicalities are concerned because of increased



vascularity and resection of the trophoblastic tissue. The use of vasopressor agents would make the vascularity significantly less even in ruptured ectopic and make laparoscopy a feasible option. Once the surgeon resects the pregnancy with the encapsulating myometrium, one has to reconstruct the corneal region with the help of interrupted sutures so that the patient can harbor a regular intrauterine pregnancy in the near future. It is also important to make sure that the entire trophoblastic tissue is resected out and to make sure with regular periodic follow-up the decline in beta-hCG values every week until it is <0.3 mIU/l. A dilatation and curettage is advisable to rule out a concomitant intrauterine pregnancy. As opposed to tubal ectopic the surgeon needs to make sure all the trophoblastic tissue is resected and in some cases also needs to cauterize the corneal ectopic tissue bed. If the raw area is extensive one may need to put an absorbable adhesion barrier to cover the serosal defect. If a surgeon is not able to maintain hemostasis or resect the trophoblastic tissue is better to convert to laparotomy. Of the three patients in our group, two are not keen on subsequent fertility.

## CONCLUSION

We present three cases of interstitial ectopic pregnancy. From analysis of literature, the authors believe that the successful management of a patient with interstitial pregnancy hinges on the premise of adequate tissue resection and sufficient hemostasis of the resected tissue bed. Laparoscopy when performed by an experienced surgeon, allows for improved surgical dexterity and can be considered a safe and effective method in the management of interstitial ectopic pregnancy.

## REFERENCES

1. Vicino M, Loverro G, Resta L, et al. Laparoscopic cornual excision in a viable large interstitial pregnancy without blood flow detected by color Doppler ultrasonography. *Fertil Steril* 2000;74(2):407-409.
2. Dilbaz S, Katas B, Demir B, et al. Treating cornual ectopic pregnancy with a single methotrexate injection. *J Reprod Med* 2005;50(2):141-143.
3. Tulandi T, Al-Jaroudi D. Interstitial pregnancy: results generated from The Society of Reproductive Surgeons Registry. *Obstet Gynecol* 2004;103(1):47-50.
4. Akkrivis Ch, Varras M, Kyparos J, et al. Early ultrasonographic diagnosis of unruptured interstitial pregnancy: a case report and review of the literature. *Clin Exp Obstet Gynecol* 2003;30(1):60-64.
5. Rock J, Thompson J. *Telinde's Operative Gynecology*. 9th ed. Philadelphia, PA: Lippincott-Raven; 2003.
6. Lau S, Tulandi T. Conservative medical and surgical management of interstitial ectopic pregnancy. *Fertil Steril* 1999;72(2):207-215.
7. Rastogi R, Meena GL, Rastogi N, et al. Interstitial ectopic pregnancy: A rare and difficult clinicasonographic diagnosis. *J Hum Reprod Sci* 2008;1(2):81-82.
8. Ackerman TE, Levi CS, Lyons EA, et al. Interstitial line: sonographic finding in interstitial (cornual) ectopic pregnancy. *Radiology* 1993;189(1):83-87.
9. Brewer H, Gefroh S, Munkarah A, et al. Asymptomatic uterine rupture of a cornual pregnancy in the third trimester: a case report. *J Reprod Med* 2005;50(9):715-718.
10. Attia M, Karuppaswamy J, Griffith H. Management of interstitial (cornual) pregnancy at 17 weeks' gestation: conservation of a ruptured uterus. *J Obstet Gynaecol* 2005;25:722-723.
11. Khawaja N, Walsh T, Gill B. Uterine artery ligation for the management of ruptured cornual ectopic pregnancy. *Eur J Obstet Gynecol Reprod Biol* 2005;118(9):269.
12. Grimbizis GF, Tsalikis T, Mikos T, et al. Case report: laparoscopic treatment of a ruptured interstitial pregnancy. *Reprod Biomed Online* 2004;9:447-451.
13. Takeda A, Manabe S, Mitsui T, et al. Management of patients with ectopic pregnancy with massive hemoperitoneum by laparoscopic surgery with intraoperative autologous blood transfusion. *J Minim Invasive Gynecol* 2006;13:43-48.
14. Tulandi T, Vilos G, Gomel V. Laparoscopic treatment of interstitial pregnancy. *Obstet Gynecol* 1995;85:465-467.
15. Grobman WA, MP Milad. Conservative laparoscopic management of a large cornual ectopic pregnancy. *Hum Reprod* 1998;13(7):2002-2004.
16. Faraj R, Steel M. Review Management of cornual (interstitial) pregnancy. *The Obstetrician and Gynaecologist* 2007;9: 249-255.
17. Soriano D, Vicus D, Mashiach R, et al. Laparoscopic treatment of cornual pregnancy: a series of 20 consecutive cases. *Fertil Steril* 2008;90(3):839.