

Case Report of Pentalogy of Cantrell

Ragweshwar Jyoti, Payal Gupta

ABSTRACT

Cantrell's pentalogy with ectopia cordis is an extremely rare and lethal congenital anomaly. We discuss the case and present a brief review of literature of embryogenesis.

Keywords: Abdominal wall defect, Cantrell's pentalogy, Ectopia cordis.

How to cite this article: Jyoti R, Gupta P. Case Report of Pentalogy of Cantrell. *J South Asian Feder Obst Gynae* 2012; 4(1):59-60.

Source of support: Nil

Conflict of interest: None declared

INTRODUCTION

The pentalogy of Cantrell was first described in 1958.¹ The hallmark of this syndrome is an omphalocele associated with ectopia cordis (EC). The full spectrum consists of five anomalies: A deficiency of the anterior diaphragm, a midline supraumbilical abdominal wall defect, a defect in the diaphragmatic pericardium, various congenital intracardiac abnormalities and a defect of the lower sternum. Only a few patients with the full spectrum of the pentalogy have been described. We reviewed the literature to find prognostic factors that may help to assess the best multidisciplinary approach in prenatal counseling and in postnatal therapy in patients with the pentalogy of Cantrell.

CASE REPORT

Mrs P came to attend OPD of our hospital for routine antenatal checkup with 5 months amenorrhea. She received one injection of tetanus toxoid and was taking iron and folic acid prophylaxis. 1st trimester was uneventful. No history of any unsupervised drug intake was there. Quickening was felt at around 20 weeks. On the day of examination, her POG was 23 w1d. Her routine investigations were normal. On per abdomen examination, uterine size was corresponding to POG and fetal parts were palpable. USG examination showed herniation of liver and stomach through anterior abdominal defect suggestive of omphalocele and heart was also visible through a lower sternal defect. MRI was done which showed extraabdominal herniation of liver and gut loops. The umbilical cord was seen passing through herniated visceral organs. The gut loops were seen freely floating without any surrounding membrane. Abdominal girth was significantly reduced. Fetal thorax was hypoplastic with a defect in the center and heart was lying outside the thoracic cage. Overall, the findings were suggestive of pentalogy of Cantrell. Decision for termination of pregnancy was taken and induction was done with misoprost tablets given intravaginally. Complete abortion of a female fetus was there. Fetus was having anterior abdominal defect above umbilicus

through which liver, stomach and gut loops were herniating. Thorax was hypoplastic with heart protruding through a sternal defect. External genitalia were normal and there was scoliosis toward left. Postabortion period was uneventful and she was discharged next day in a good condition.

DISCUSSION

The pentalogy of Cantrell is an extremely rare congenital anomaly. The complexity of this syndrome is usually incompatible with life, so the exact incidence could not be found in the literature; however, an incidence of 1:100000 births, with a male preponderance (M:F = 2:1.2), has been described in literature in developed countries.² Cantrell, Haller and Ravitch, in 1958, were the first to describe this syndrome.¹ Displacement or eventration of the heart through the abdominothoracic wall defect is called ectopia cordis. Depending on the location of the protruding heart and on the extent of the body wall defect, ectopia cordis may be grouped into cervical, thoracic, thoracoabdominal or abdominal types. The heart was uncovered in 41%, covered with a serous membrane in 31% and covered with skin in 27% of reported cases.³ In thoracoabdominal ectopia, as in our case, the body wall usually remains unclosed up to the umbilicus. The diaphragm has a V-shaped hiatus. The anterior and inferior portion of the pericardium may be absent. The heart itself may be congenitally abnormal as well as displaced.

The entire group of anomalies would appear to be closely related in embryologic development, arising as the result of defective formation and differentiation of the ventral mesoderm at about 14 to 18 days of embryonic life. On the basis of embryological development, this syndrome may be classified into two groups. The first group arises as the result of developmental failure of a segment of the mesoderm and comprises three of the defects, i.e. diaphragmatic defect (which results from total or partial failure of the transverse septum to develop); pericardial defect (which is closely related to faulty development of the transverse septum); and intracardiac lesions (which is the result of faulty development of the epimyocardium, which is derived from the splanchnic mesoderm). The second group includes the sternal and abdominal wall defect and appears to arise due to failure of migration of the paired primordial structures.¹ Many variants of Cantrell's pentalogy have been described according to the postulated embryological development of these defects;^{1,4,5} these various types may be classified as follows:²

Class 1: Exact diagnosis, with the five defects present

Class 2: Probable diagnosis, with four defects (including intracardiac and abdominal wall defects) present

Class 3: Incomplete diagnosis, with combination in the defects (always accompanied by sternal defects).

The occurrence of congenital intracardiac anomalies is a constant element of this syndrome; a ventricular septal defect was present in every instance in which a description of the heart was available, and was also found in our case.^{1,3} Other intracardiac anomalies that are seen include atrial septal defect (53%), valvular or infundibular pulmonary stenosis (33%), tetralogy of Fallot (20%), left ventricular diverticulum (20%), etc.¹ With the increasing use of antenatal diagnostic tools, these anomalies can be diagnosed before birth (Fig. 1).^{2,3}

With prenatal ultrasonography, the pentalogy of Cantrell usually can be diagnosed in the first trimester of pregnancy.⁶ In a fetus with omphalocele, pentalogy of Cantrell should be ruled out. If pericardial effusion can be seen, associated anterior diaphragmatic hernia and diaphragmatic pericardial defects may be suspected and specific and detailed search for the features of the pentalogy of Cantrell should be done.⁷ Use of prenatal magnetic resonance imaging (MRI) may enhance the visualization of the fetal anomalies.⁸

Although most cases of the ectopia cordis appear as isolated, sporadic defects, other associated anomalies, including chromosomal abnormalities (trisomy 18) are reported in literature.⁹ Carmi et al⁷ described cleft lip, with or without cleft palate, and encephalocele associated with ventral midline anomalies within the spectrum of Cantrell's pentalogy as a subunit of the midline developmental anomalies.¹⁰ In our case, cytogenetic analysis was not performed and there was no other associated anomaly.

Treatment should consist of immediate surgical repair (except for the intracardiac abnormalities); some cases that had successful surgical correction have been mentioned in literature.^{1,3-5} The prognosis in cases of ectopia cordis is much worse, with cases of thoracoabdominal ectopia showing slightly better prognosis than the other ectopias.³

In our case, the fetus had thoracoabdominal ectopia cordis with Cantrell's pentalogy and, therefore, she belongs to class 1 of the embryological classification.

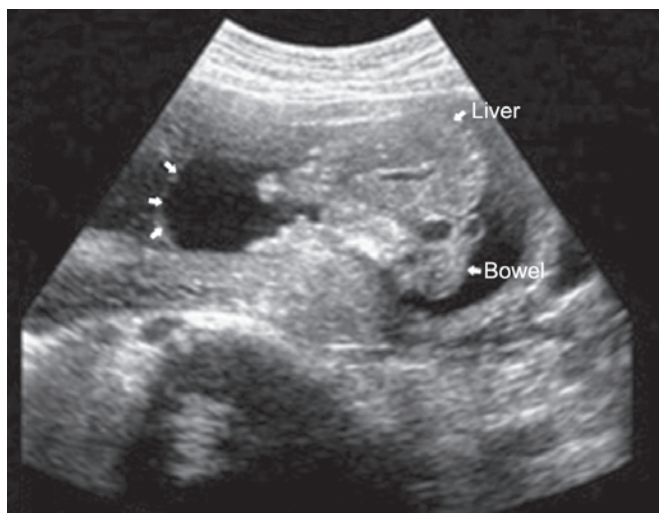


Fig. 1: Antenatal ultrasound at 23 weeks 1-day gestation demonstrating the covering of the omphalocele (arrows on the left) and the herniated liver and bowel loops. Ectopia cordis is also present

CONCLUSION

Cantrell's pentalogy with ectopia cordis is a lethal anomaly and prompt medical and surgical interventions are required immediately after birth without which death is the rule. Even after proper surgical interventions, the prognosis is not good.

REFERENCES

1. Cantrell JR, Haller JA, Ravitch MM. A syndrome of congenital defects involving the abdominal wall, sternum, diaphragm, pericardium and heart. *Surg Gynecol Obstet* 1958;107:602-14.
2. Lopez JA, Lopez AG, Leon IH. Presentation and discussion of a patient with pentalogia of Cantrell. *Cuban Rev Obstet Gynecol* 2004;30:2.
3. Skandalakis JE, Gray SW, Ricketts R, Skandalakis LJ. The anterior body wall. In: Skandalakis JE, Gray SW (Eds). *Embryology for surgeons* (2nd ed). Baltimore, MD: Williams and Wilkins 1994:552-59.
4. Sanchís Solera L, Beltrá Picó R, Castro Sánchez M, Serrano González A, Sánchez López JM, Hernández Navarro J, et al. Cantrell's pentalogy: Complete treatment, step by step. *Cir Pediatr* 1992;5:101-04.
5. Chen LJ, Wu JM, Yang YJ, Wang JN, Lin CS. Cantrell's syndrome in an infant. *J Formos Med Assoc* 1997;96:288-90.
6. Liang RI, Huang SE, Chang FM. Prenatal diagnosis of ectopia cordis at 10 weeks of gestation using two-dimensional and three-dimensional ultrasonography. *Ultrasound Obstet Gynecol* 1997; 10:137-39.
7. McMahon CJ, Taylor MD, Cassidy CI, Olutoye OO, Bezold LI. Diagnosis of pentalogy of Cantrell in the fetus using magnetic resonance imaging and ultrasound. *Pediatr Cardiol* 2007;28: 172-75.
8. Siles C, Boyd PA, Manning N, Tsang T, Chamberlain P. Omphalocele and pericardial effusion: Possible sonographic markers for the pentalogy of Cantrell or its variants. *Obstet Gynecol* 1996;87:840-42.
9. Bick D, Markowitz RI, Horwich A. Trisomy 18 associated with ectopia cordis and occipital meningocele. *Am J Med Genet* 1988;30:805-10.
10. Carmi R, Boughman JA. Pentalogy of Cantrell and associated midline anomalies: A possible ventral midline developmental field. *Am J Med Genet* 1992;42:90-95.

ABOUT THE AUTHORS

Ragweshwar Jyoti

Gynecologist, Department of Obstetrics and Gynecology, DDUZH Shimla, Himachal Pradesh, India

Payal Gupta

Senior Resident, Department of Plastic Surgery, Indira Gandhi Medical College, Shimla, Himachal Pradesh, India

CORRESPONDING AUTHOR

Ragweshwar Jyoti, C-505, Ground Floor, Near DAV School Sector 4, New Shimla, Shimla, Himachal Pradesh, India, e-mail: drjyoti1973@yahoo.com