

A Rare Case of Vaginal Leiomyoma Diagnosed Postoperatively

¹Deepti Shrivastava, ²Sindhu Bhute, ³Anuradha Kakani, ²Vijya Patil, ¹Shubhda Jajoo, ⁴Shikha Joshi

¹Associate Professor, Department of Obstetrics and Gynecology, Jawahar Lal Nehru Medical College, AVBRH, DMIMS Wardha, Maharashtra, India

²Professor, Department of Obstetrics and Gynecology, Jawahar Lal Nehru Medical College, AVBRH, DMIMS Wardha, Maharashtra, India

³Lecturer, Department of Obstetrics and Gynecology, Jawahar Lal Nehru Medical College, AVBRH, DMIMS Wardha, Maharashtra, India

⁴Resident, Department of Obstetrics and Gynecology, Jawahar Lal Nehru Medical College, AVBRH, DMIMS Wardha, Maharashtra, India

Correspondence: Deepti Shrivastava, Associate Professor, Department of Obstetrics and Gynecology, M-4, Meghdoot Apartments, JNMC Campus, Sawangi, Meghe, Wardha-420001, Maharashtra, India, Phone: 09860817801 e-mail: deepti_shrivastava69@yahoo.com

ABSTRACT

Vaginal fibroids are very rare tumor of vagina and it is difficult to rule out its origin as a primary vaginal or its connection with cervix or uterus preoperatively. We are presenting a case of vaginal fibroid diagnosed postoperatively.

Keywords: Vaginal myoma, AVBRH, Postoperative.

INTRODUCTION

Vaginal fibroids are rare to exist as a primary tumor of vagina. Approximately 300 cases have been reported in world literature.¹ Here, we are reporting a case which was diagnosed as a cervical leiomyoma preoperatively but found to had no connection with cervix or uterus intraoperatively.

CASE REPORT

A 48-year-old P2L2 was admitted to general surgery ward on 4th February 2004 as a case of urinary retention with some painless, slowly growing, hard mass protruding through the introitus during squatting, coughing or sneezing of 2 to 3 years duration.

On ultrasonography uterus, cervix and adnexa were normal with some hypoechoic mass posterior to urinary bladder displacing it. On CT scan mass was diagnosed as a cervical fibroid, hence case was transferred to obstetrics and gynecology ward. Her examination under anesthesia was planned, in which a firm to hard mass was recognized at anterior vaginal wall of approximately 8 × 4 × 3 cm in size. It was mobile side to side only and cervix was pushed so high up that it was difficult to catch (Fig. 1).

As her general condition, other radiological and laboratory investigations were within normal limit, and medical and surgical history were nonsignificant, in view of cervical fibroid, decision of total vaginal hysterectomy was made. At first the lowermost portion of the bulge was caught by Allice forceps and transverse incision was given over anterior vaginal wall because cervix was very high up and difficult to catch hold. As the vaginal mucosa was separated from the mass, it came out very easily just like enucleated myoma without any efforts. The

gross characteristics of the mass were typical of fibroids only with its bed at the lower 1/3rd of vagina and, to our great surprise, it was not having any connection to cervix. Mass was 9 × 5 × 3 cm in size and 130 gm in weight. It was far away from cervix and rest of the hysterectomy was completed as conventional method along with bilateral salpingo-oophorectomy. Bed of myoma was closed carefully with special care of urethra, and excess of vaginal mucosa was excised as we do in anterior colporrhaphy (Fig. 2).

After hysterectomy, again the specimen was observed for any connection with cervix or uterus but there was no evidence. Postoperative period was uneventful, catheter was removed on 5th day (Fig. 3). Histopathological report came out as leiomyoma (Fig. 4).

DISCUSSION

Mostly leiomyomas are benign tumors of myometrium only, although uncommon loci have also been described in the round ligament, broad ligament, urinary bladder, in the renal pelvis, spermatic cord, glans penis, urethra and even in the peritoneum.² Vaginal origin is very rare¹⁻⁵ with approximately 300 cases reported in the world literature.^{1,3} In the vagina, they commonly present through anterior wall and next through the lateral wall.^{1-4,6} They may arise from posterior wall,⁵ may present even after hysterectomy⁶ and in the form of ischio-rectal abscess too.³ Very often diagnosis of them is difficult to be made preoperatively.^{1,3,5}

They are slowly growing and generally asymptomatic^{1,2} but may give rise to cyclic urinary retention,^{1,6,8} dyspareunia,^{2,4,6} gluteal swelling with vaginal purulent discharge,³ pain in abdomen,⁵ obstruction to birth passage if along with pregnancy⁷ or simply with feeling of mass in vagina.^{1,2,4,6}

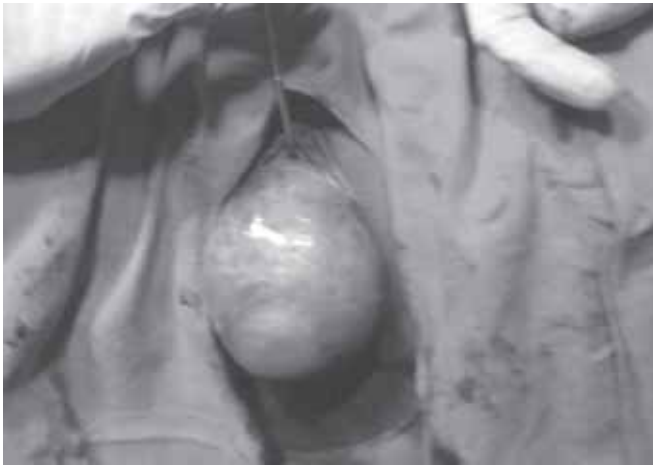

Fig. 1: Preoperative appearance of tumor




Fig. 4: Histopathological appearance confirming leiomyoma

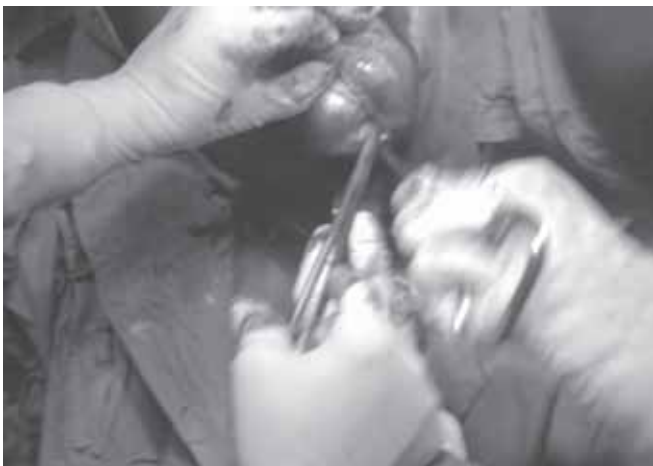

Fig. 2: Enucleation of fibroid after transverse incision over anterior vaginal wall



Fig. 3: Postoperative specimen of fibroid and uterus

On ultrasonography, it may appear as mixed or hypoechoic lesion but it is difficult to rule out any connection with uterus or cervix. CT scan, USG and biopsy are helpful to differentiate in between benign and malignant masses.³

Surgery by vaginal route is the main modality of treatment and generally it is easy because of availability of good cleavage plain.^{2-4,7}

Some cases require abdominal⁵ or abdominopelvic approach.^{3,4,8} Some recommended removal of ovaries along with uterus.⁶ If diagnosis could be made preoperatively, GnRh analog can be tried to reduce their size^{1,2} or preoperative embolization can be performed before excision to reduce intraoperative blood loss.⁴

REFERENCES

1. Park SJ, Choi SJ, Han KH, Park KH, Chung H, Song JM. Leiomyoma of the vagina that caused cyclic retention. *Acta Obstetrica et Gynecologica* 2007;86:102-10.
2. Theodoridis TD, Zepiridis L, Chatzigeorgiou KN, Papanicolaou A, Bontis JN. Vaginal wall fibroid. *Arch Gynecol Obstet* 2008; 278:281-82.
3. Gowri R, Soundararaghvan S, Oumachigui A, Sistla SC, Iyengar KR. Leiomyoma of the vagina: An unusual presentation. *J Obstet Gynaecol Res* 2003;29(6):395-98.
4. Bapuraj JR, Ojili V, Singh SK, Prasad GRV, Khandelwal N, Suri S. Preoperative embolisation of a large vaginal leiomyoma: Report of a case and review of literature. *Australian Radiology* 2006;50:179-82.
5. Gupta V, Arya P, Gupta V, Rawat DS. A rare case of vaginal fibroid presenting as ovarian tumour. *J Obstet Gynecol India* 2006;56(6):537-38.
6. Kullarni Y, Maheshwari A, Kerkar R, Agarwal R, Wuntkal R, Tongaonkar H. Vaginal leiomyoma developing after hysterectomy: Case report and literature review. *Australian and New Zealand Journal of Obstetrics and Gynaecology* 2005;45:96-97.
7. Lucas J, Dreyfus M, Bekkari Y. Surgical management during labour of giant vaginal fibromyoma. *Journal of Gynaecological Surgery* 2004;20(1):17-19.
8. Kuramoto T, Nishizawa S, Mori T, Iba A, Fuji R, Nanpou Y, Matusmura N, Shintani Y, Inagaki T, Kohjimoto Y, Hara I. Giant paraurethral leiomyoma in the female: A case report. *Hinyokika Kyo* Oct 2008;54(10):677-80.